

Unit 3 Pictures

BIOL 213 Online Lab PowerPoint

Hint: Slides with colored backgrounds help to divide content into different days.

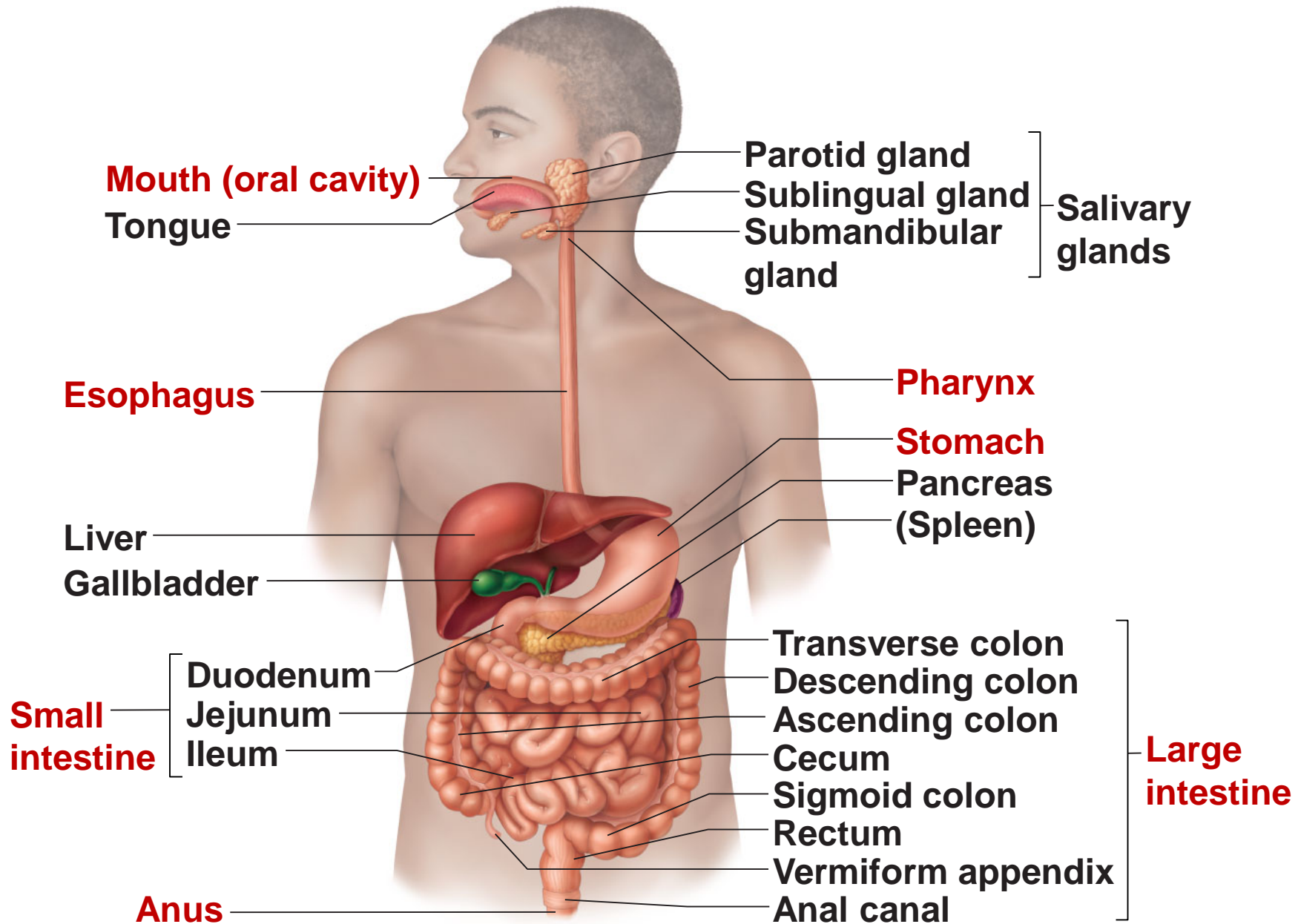
Digestive Gross Anatomy

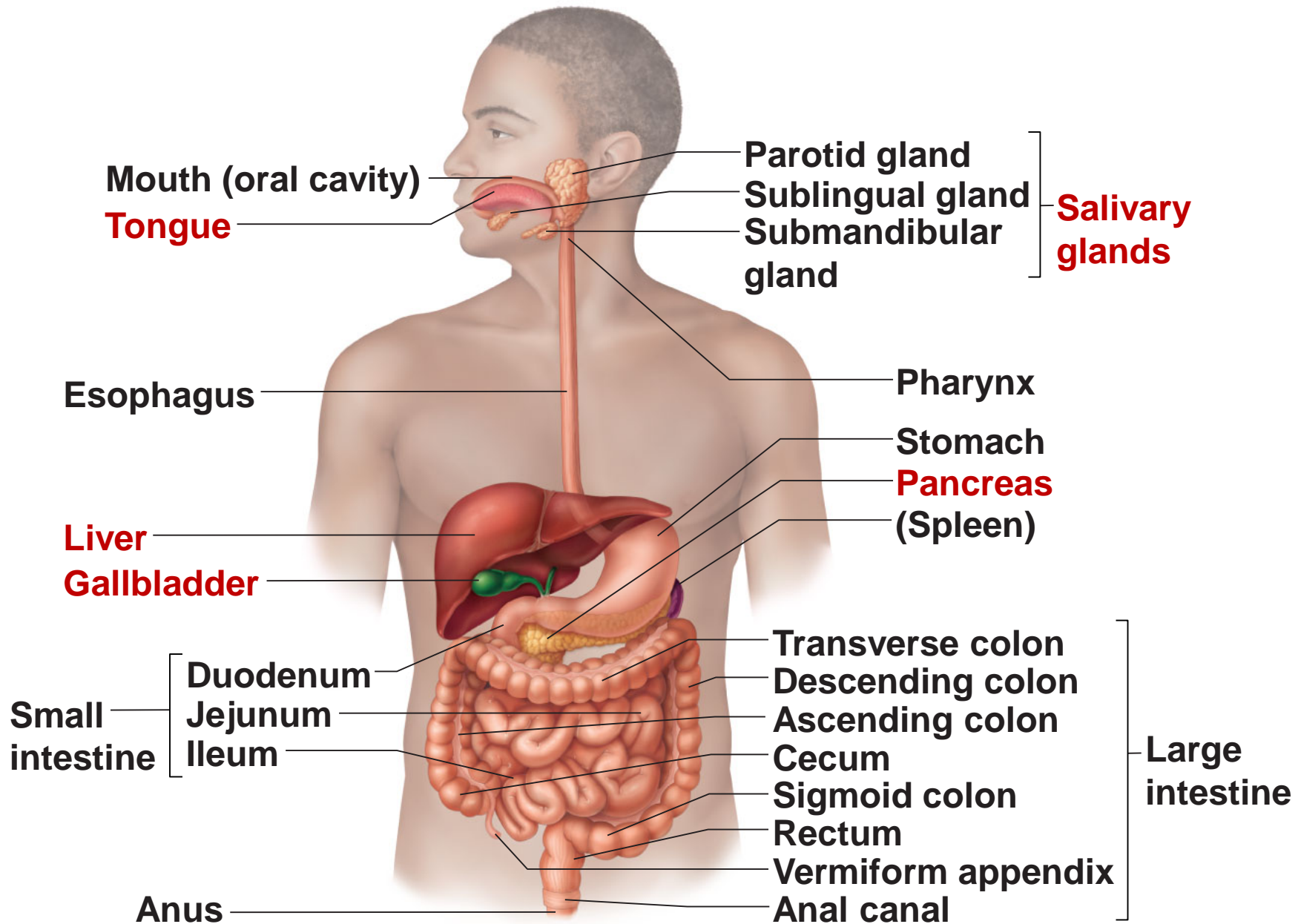
Use the following pictures to help you identify terms from the lab term handout.

***You always only need to know the terms listed in the lab term handout!

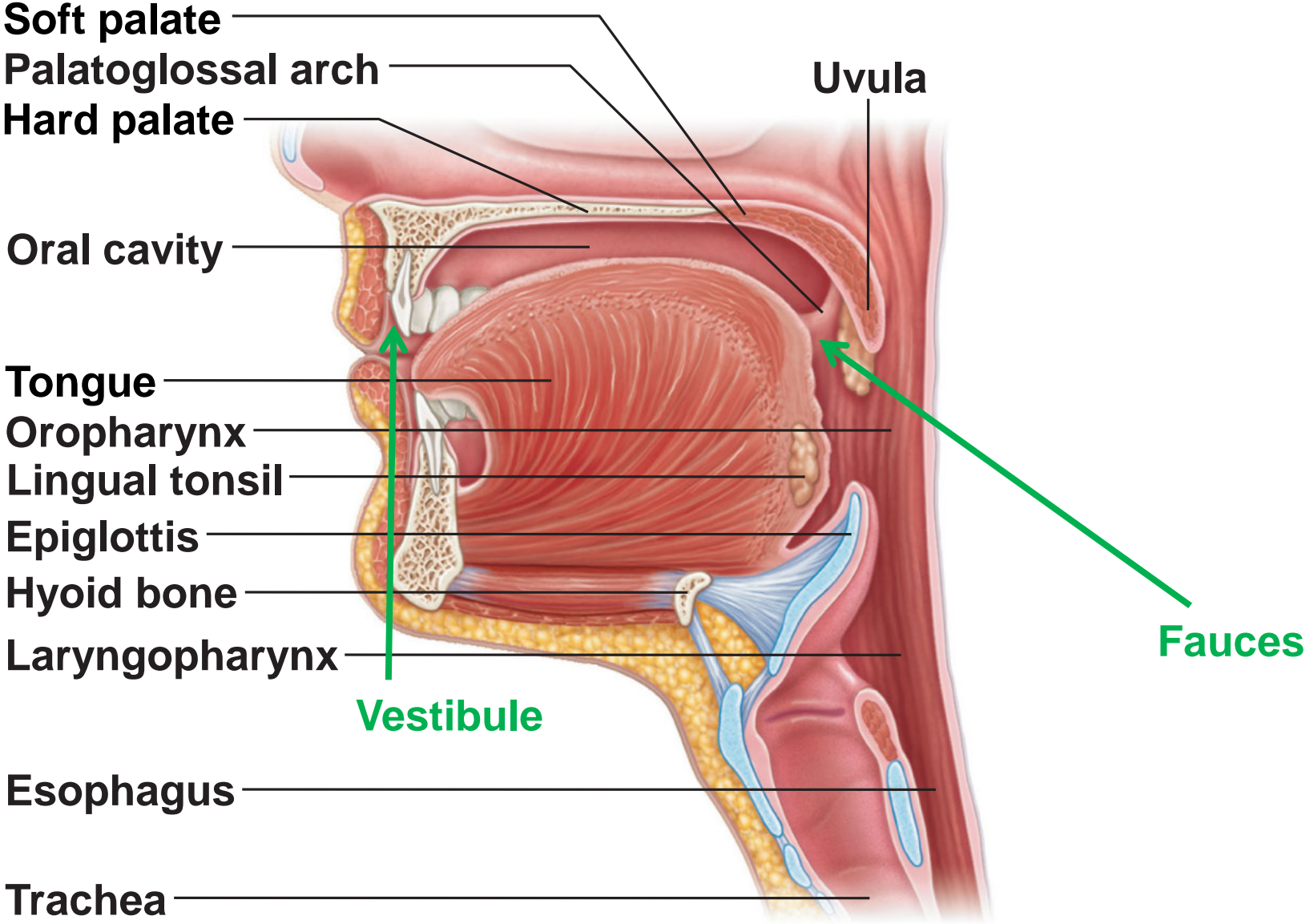
Another good resource is the Visible Body ATLAS app: <http://atlas.visiblebody.com>

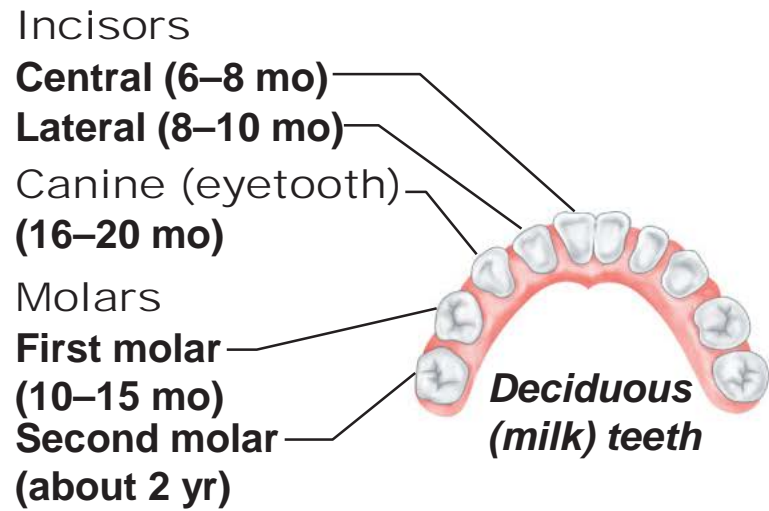
Don't forget that to use the link to download the atlas to a personal device, the device must first be connected to the MCPA Wi-Fi at the Rockville campus.





Mouth: Oral (buccal) cavity





(a)

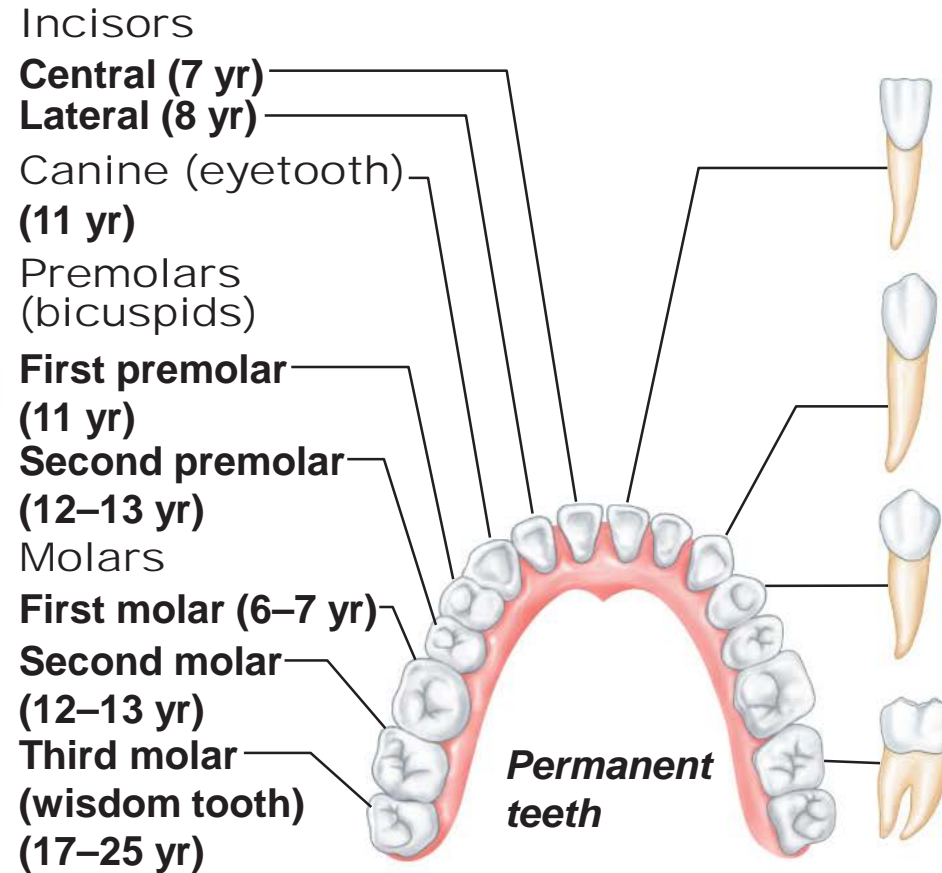


Figure 23.10a

Regions:

Layers:

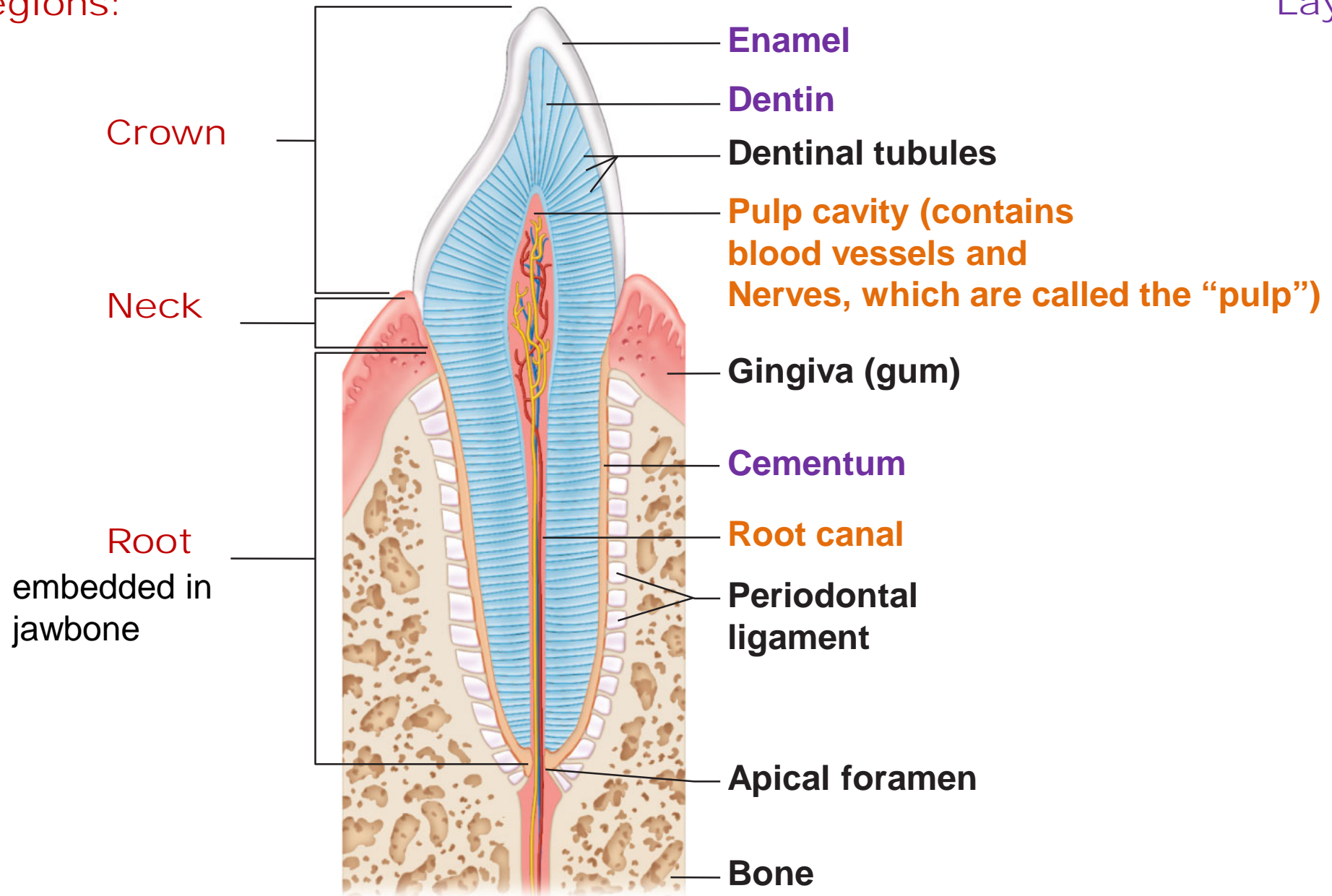


Figure 23.11

Regions:

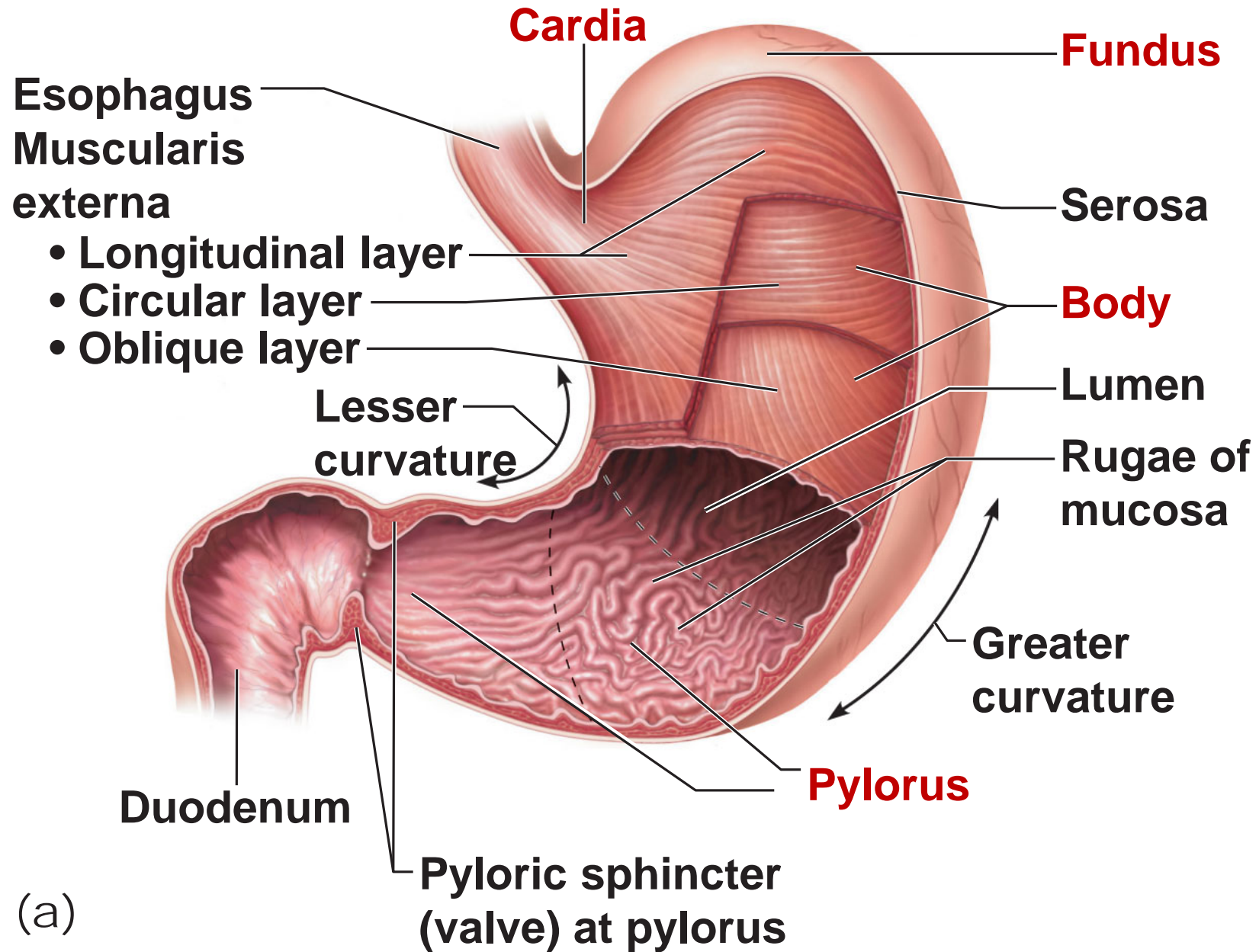


Figure 23.14a

Liver

Gallbladder

Lesser omentum

Stomach

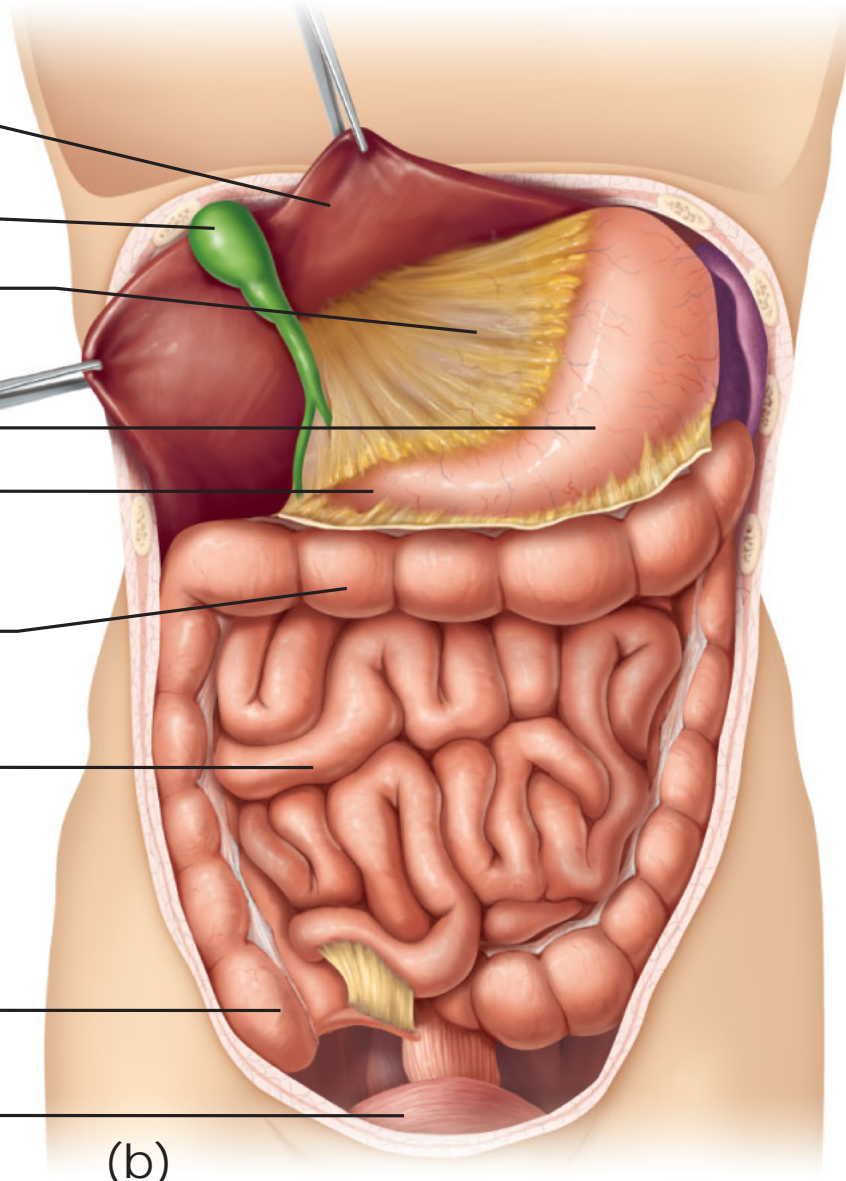
Duodenum

Transverse colon

Small intestine

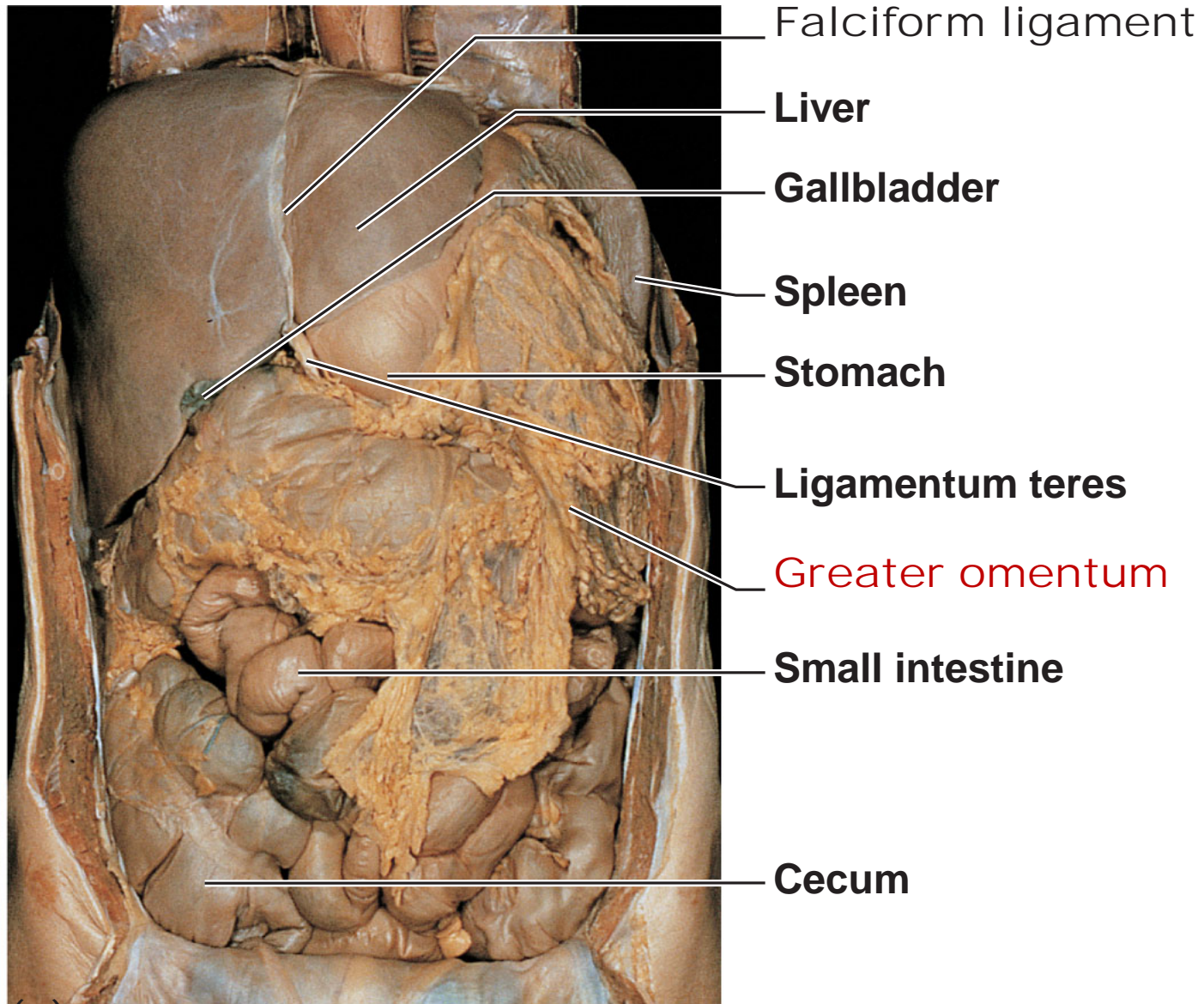
Cecum

Urinary bladder

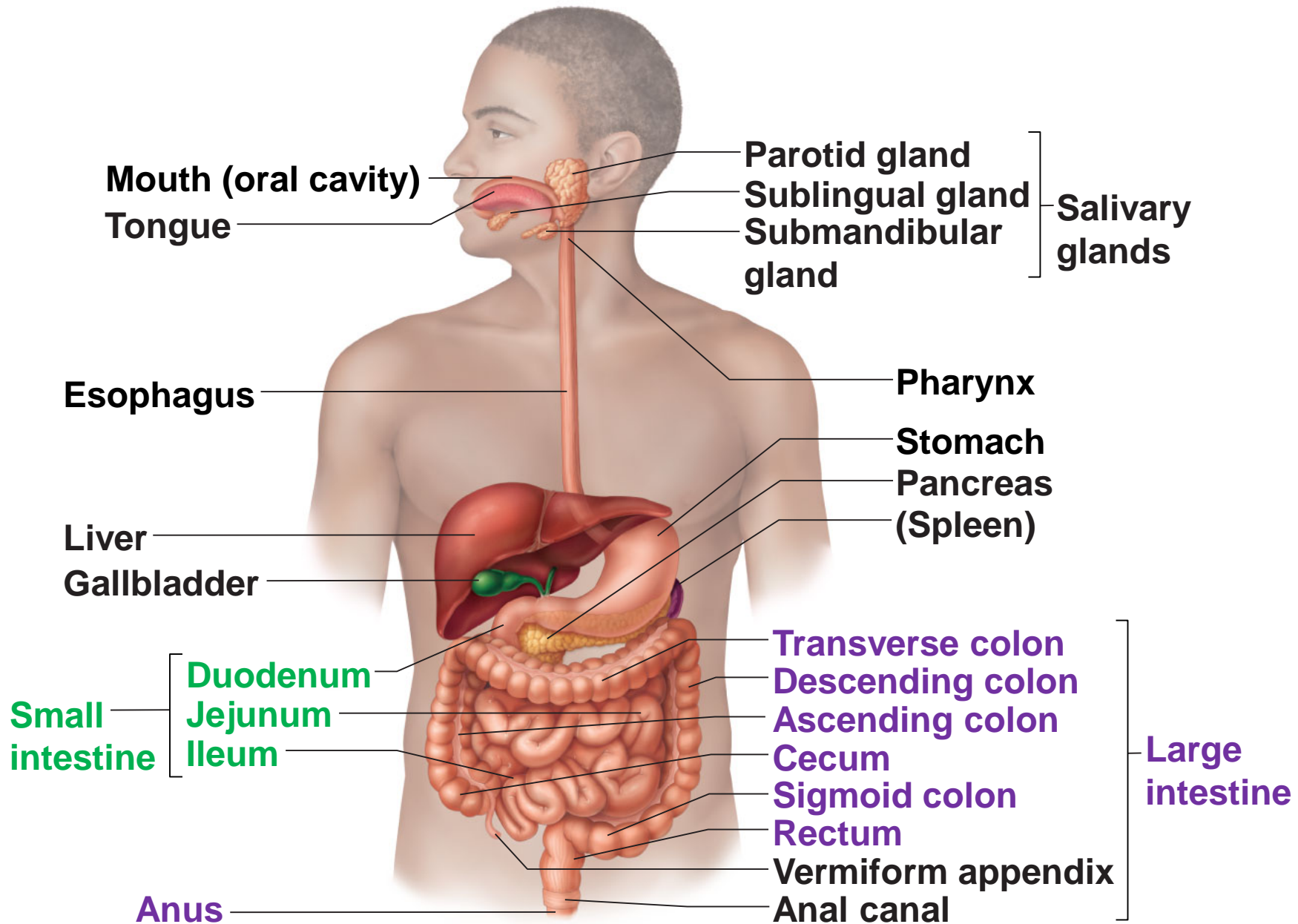


(b)

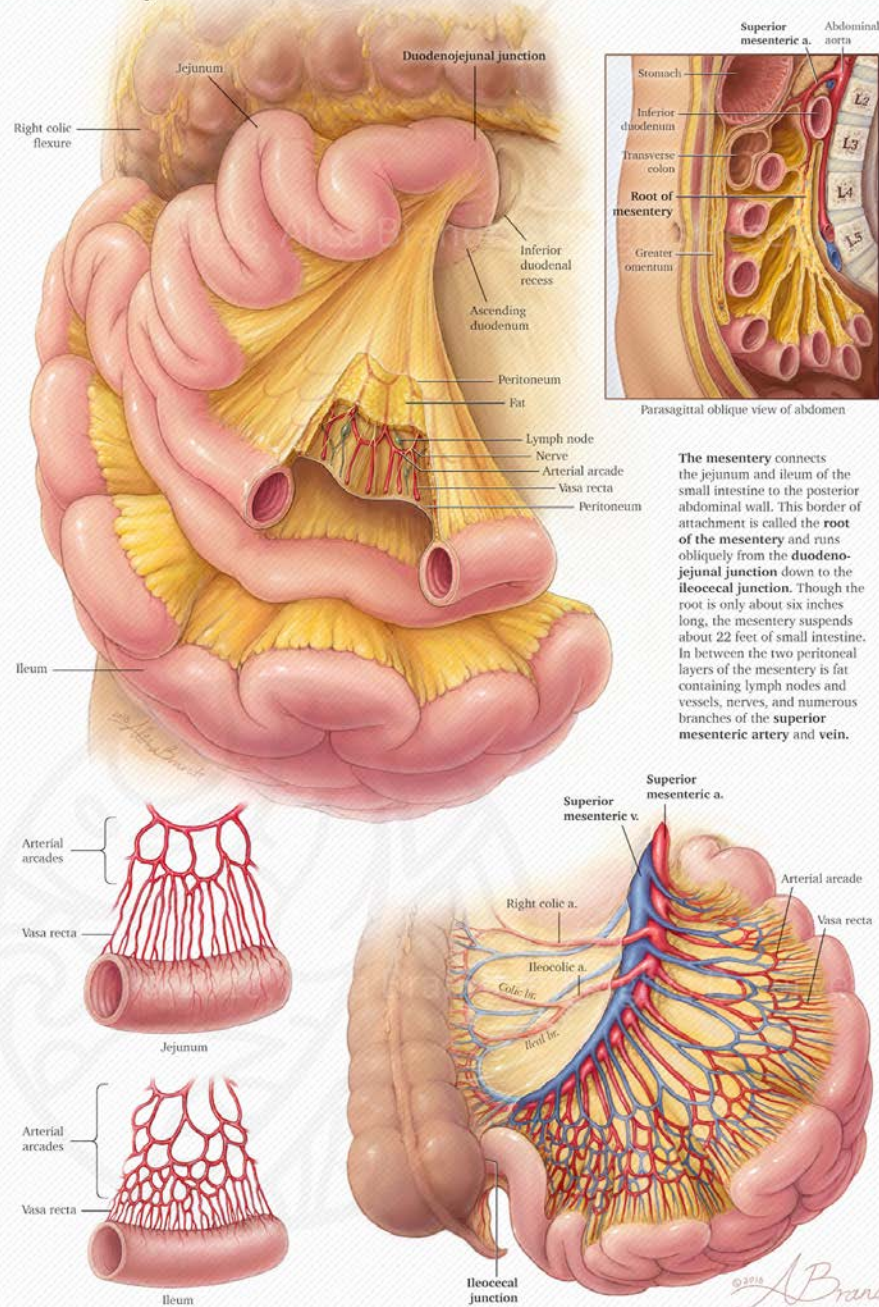
Figure 23.30b



(a)



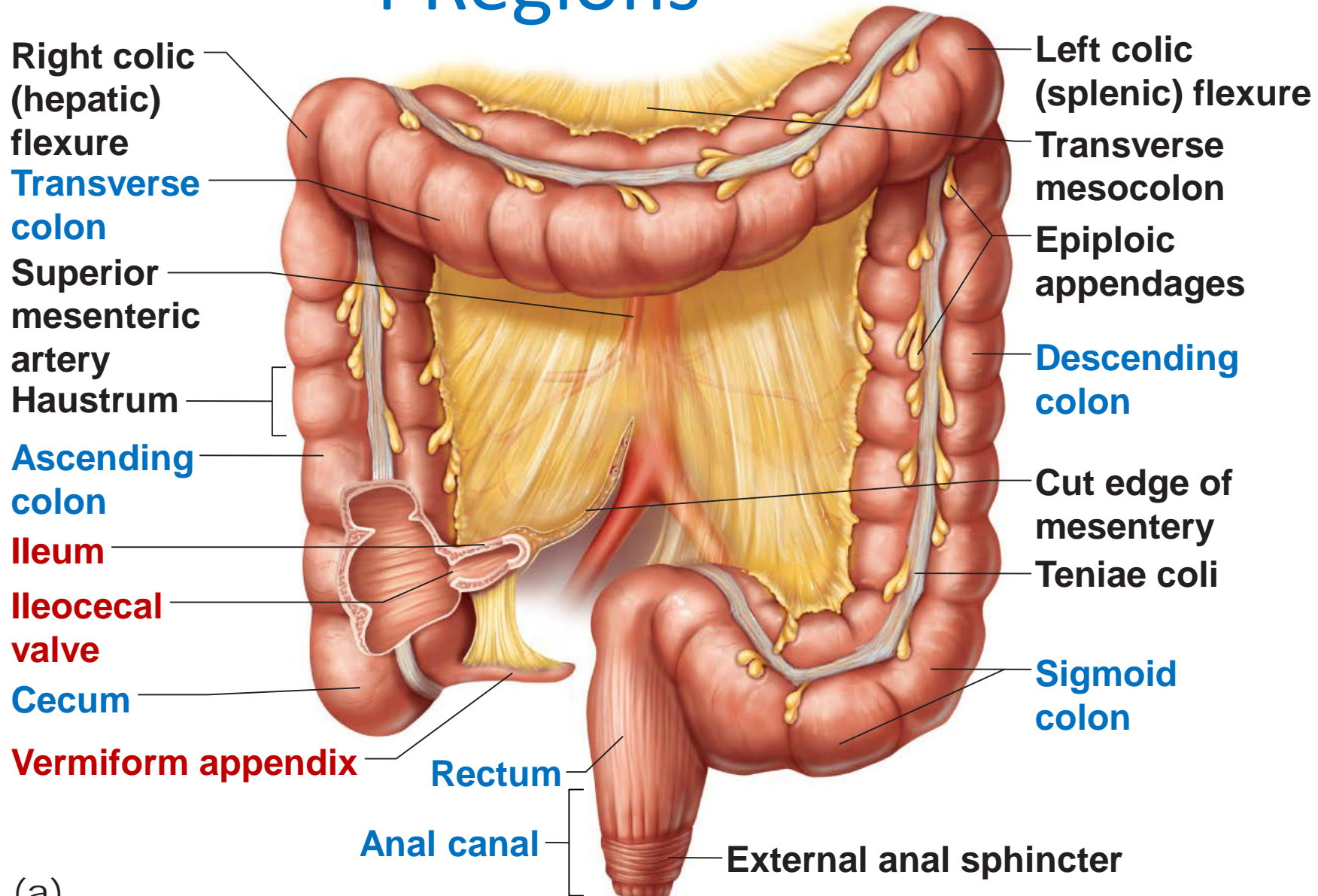
Mesentery & Mesenteric Vessels of the Small Intestine



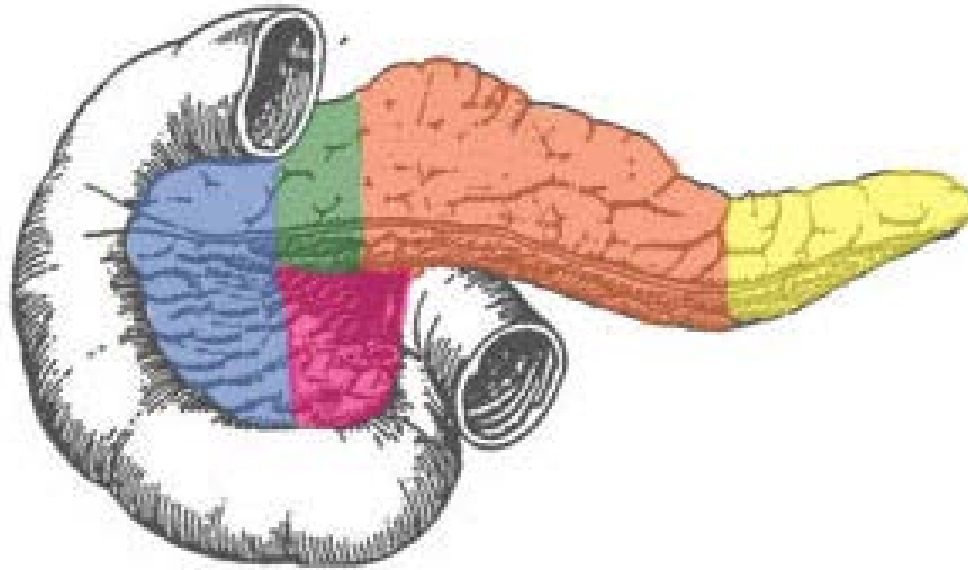
Copy this image to word to enlarge for better viewing.

The key difference between Mesentery and the Greater and Lesser Omentum is that mesentery has blood vessels associated with the connective tissues and the others do not.


4 Regions



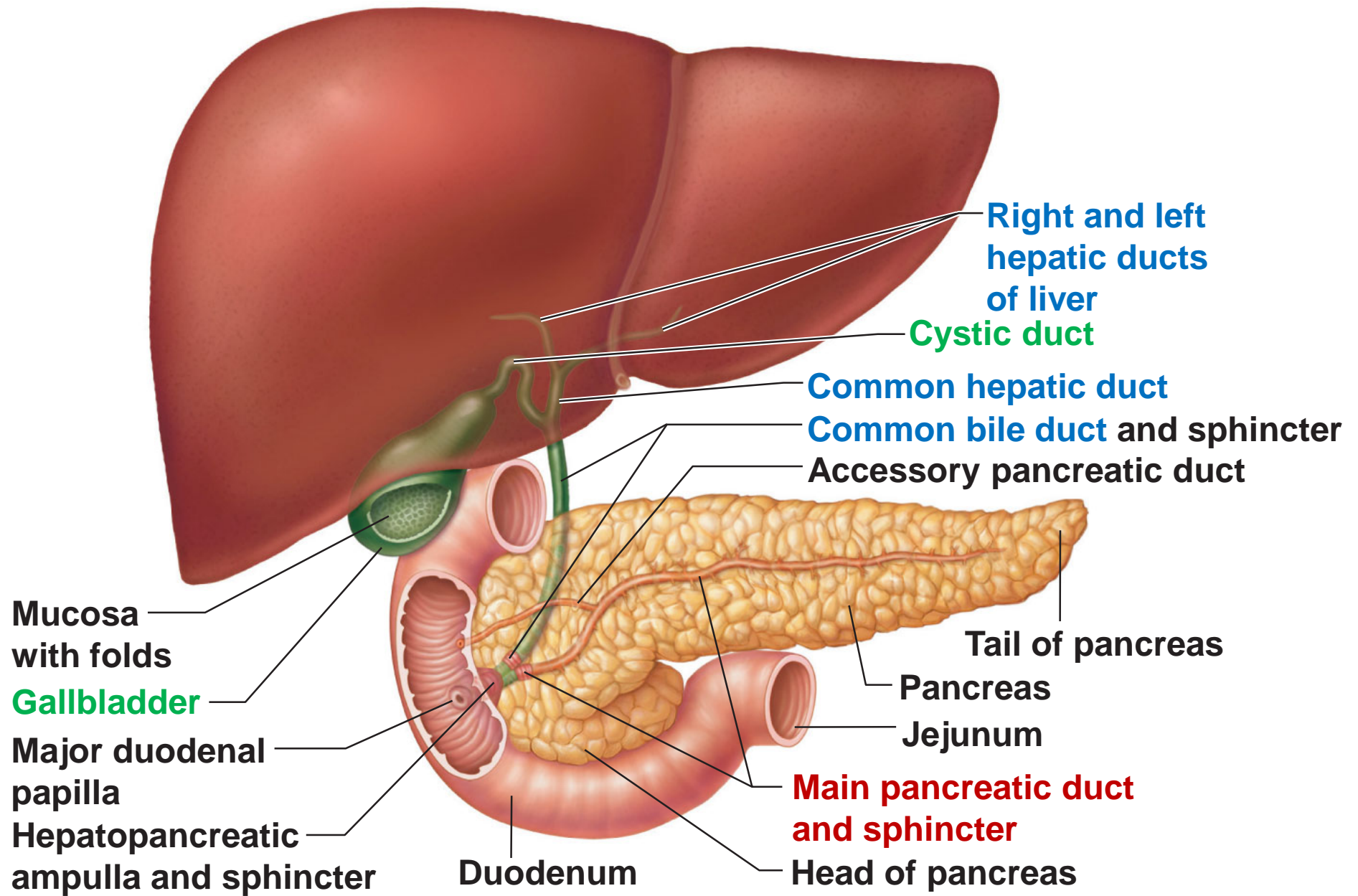
(a)



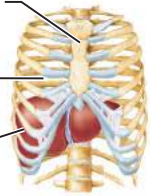
- Uncinate process
- Head
- Neck
- Body
- Tail



You can consider this part of the neck for our class.



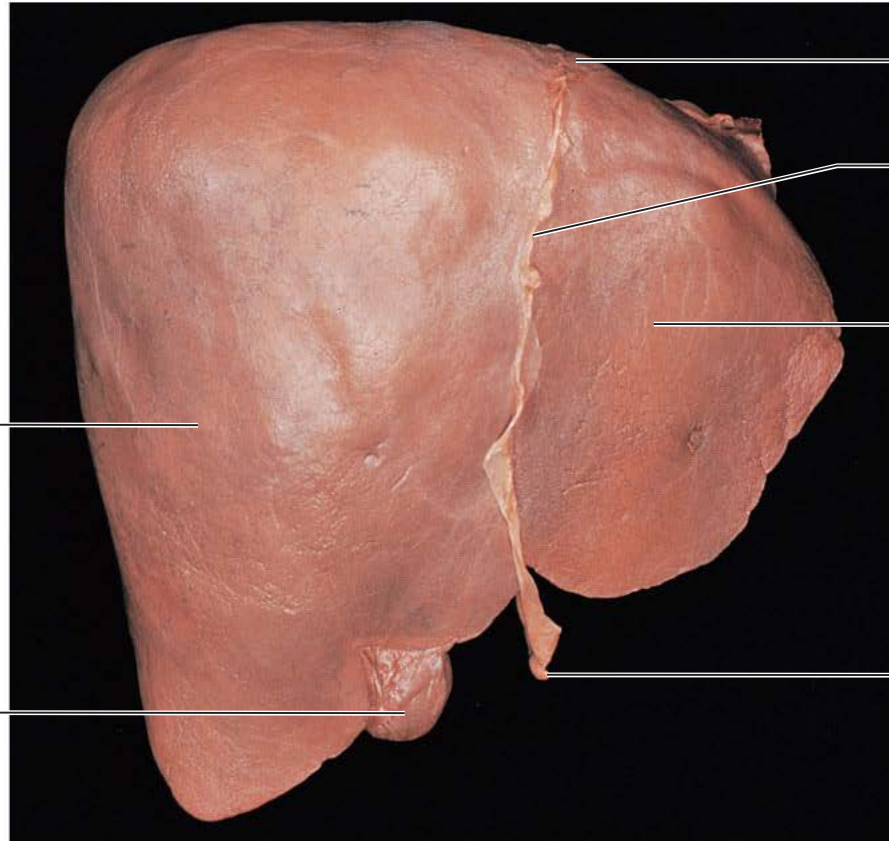
Sternum
Nipple
Liver



Right lobe
of liver

Gallbladder

(a)

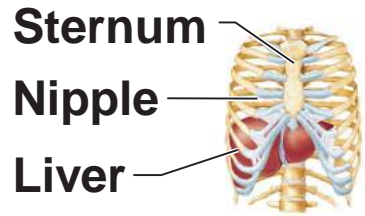


Bare area

Falciform
ligament

Left lobe of liver

Round ligament
(ligamentum
teres)



Lesser omentum
(in fissure)

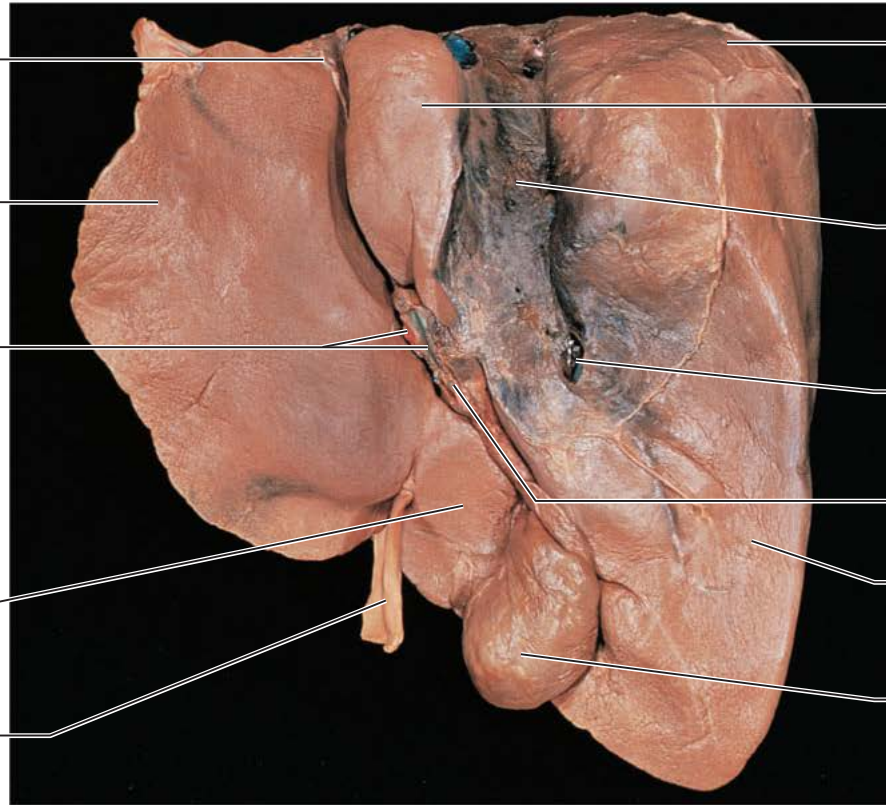
Left lobe of liver

Porta hepatis
containing hepatic
artery (left) and
hepatic portal vein
(right)

**Quadrate lobe
of liver**

Ligamentum teres

(b)



Bare area

**Caudate lobe
of liver**

Sulcus for
inferior
vena cava

Hepatic vein
(cut)

Bile duct (cut)

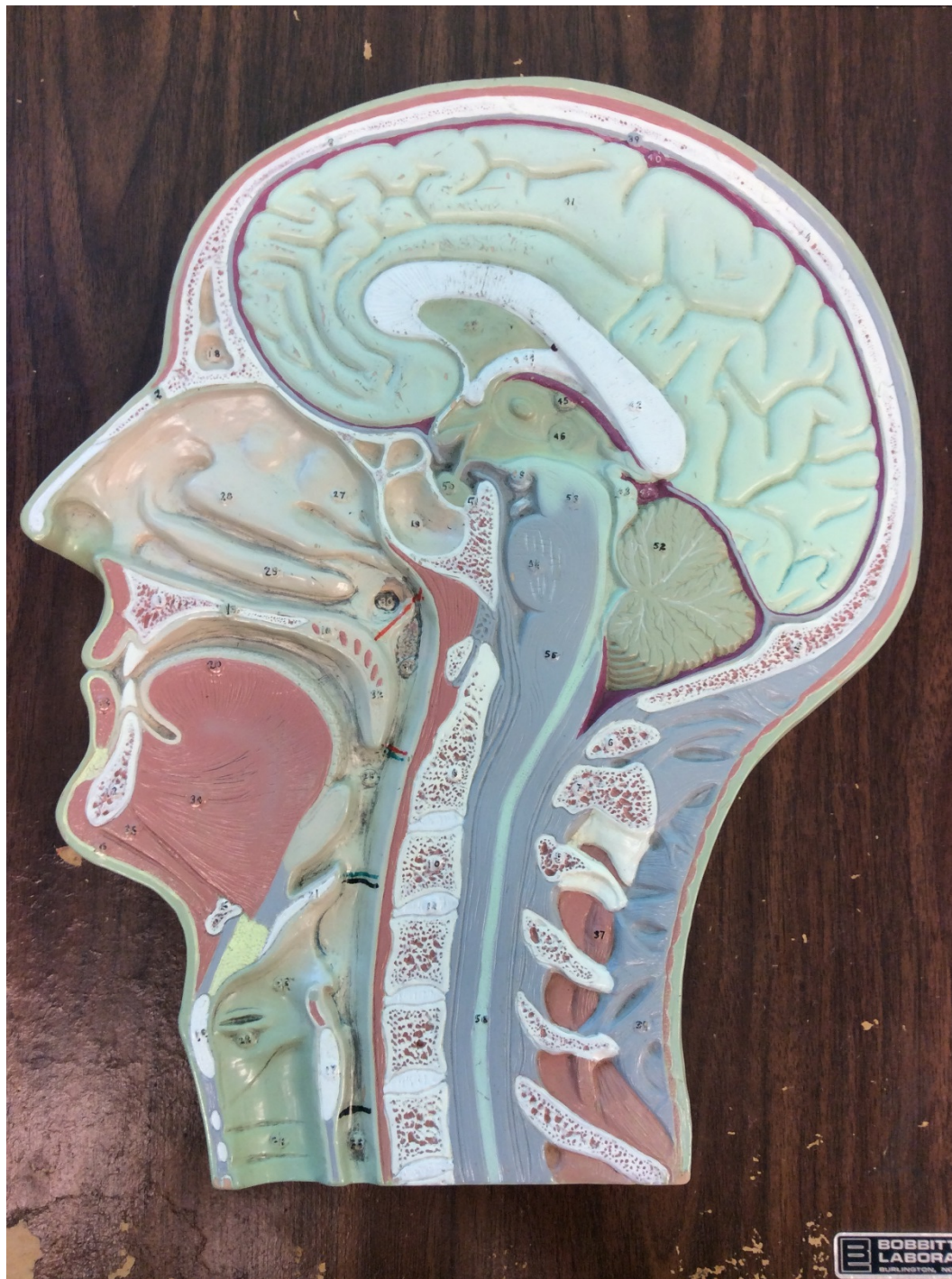
**Right lobe of
liver**

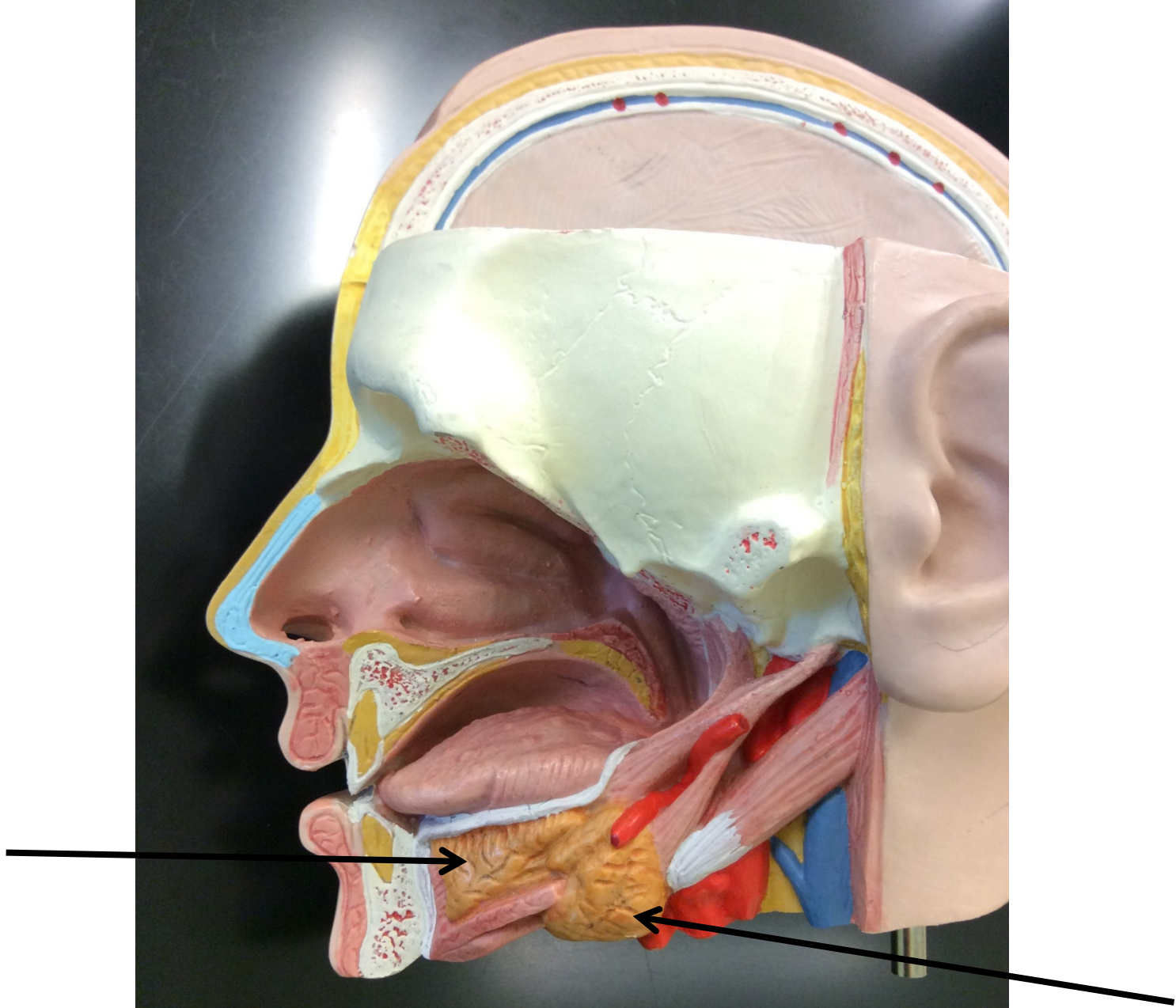
Gallbladder

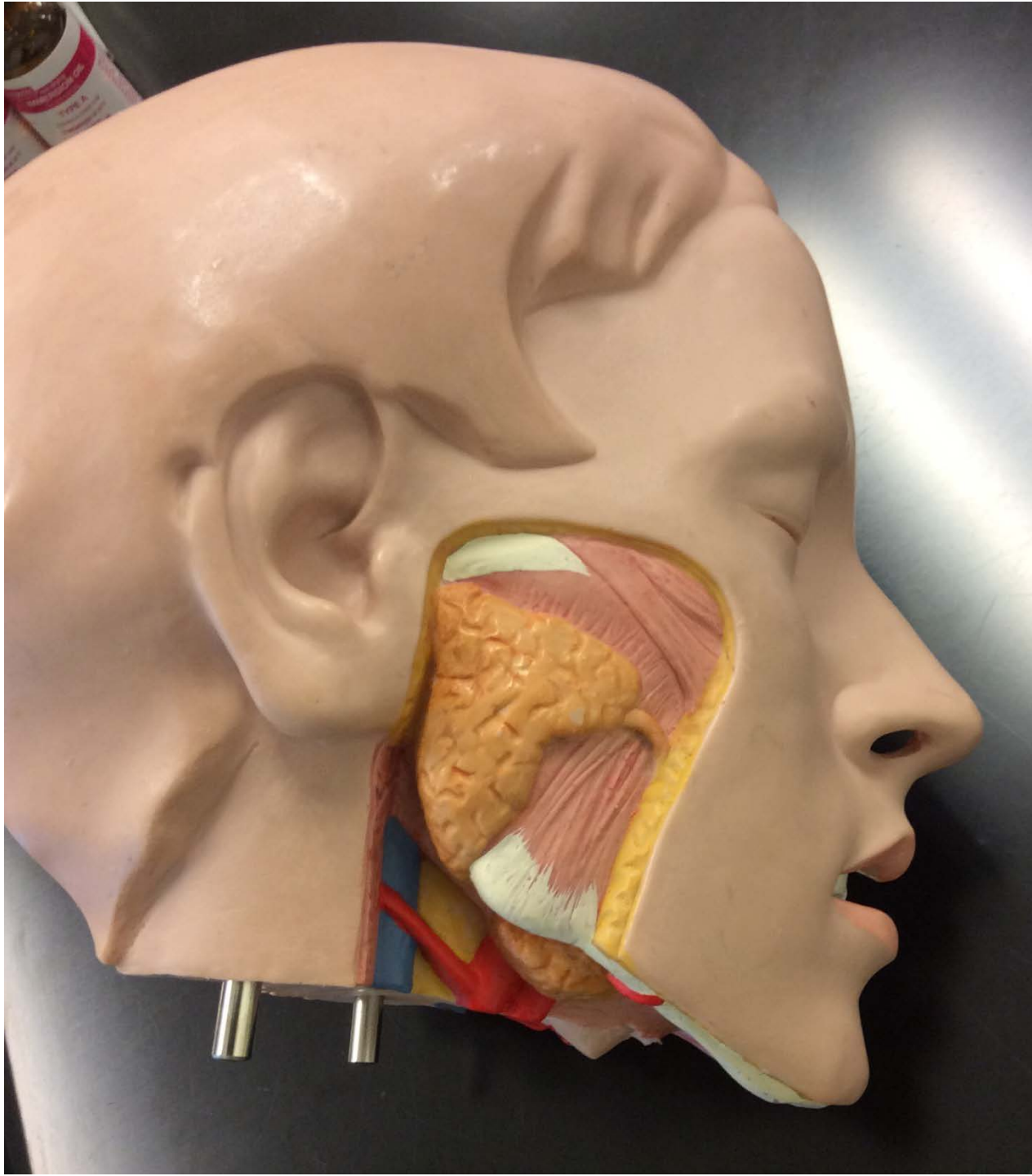
Figure 23.24b

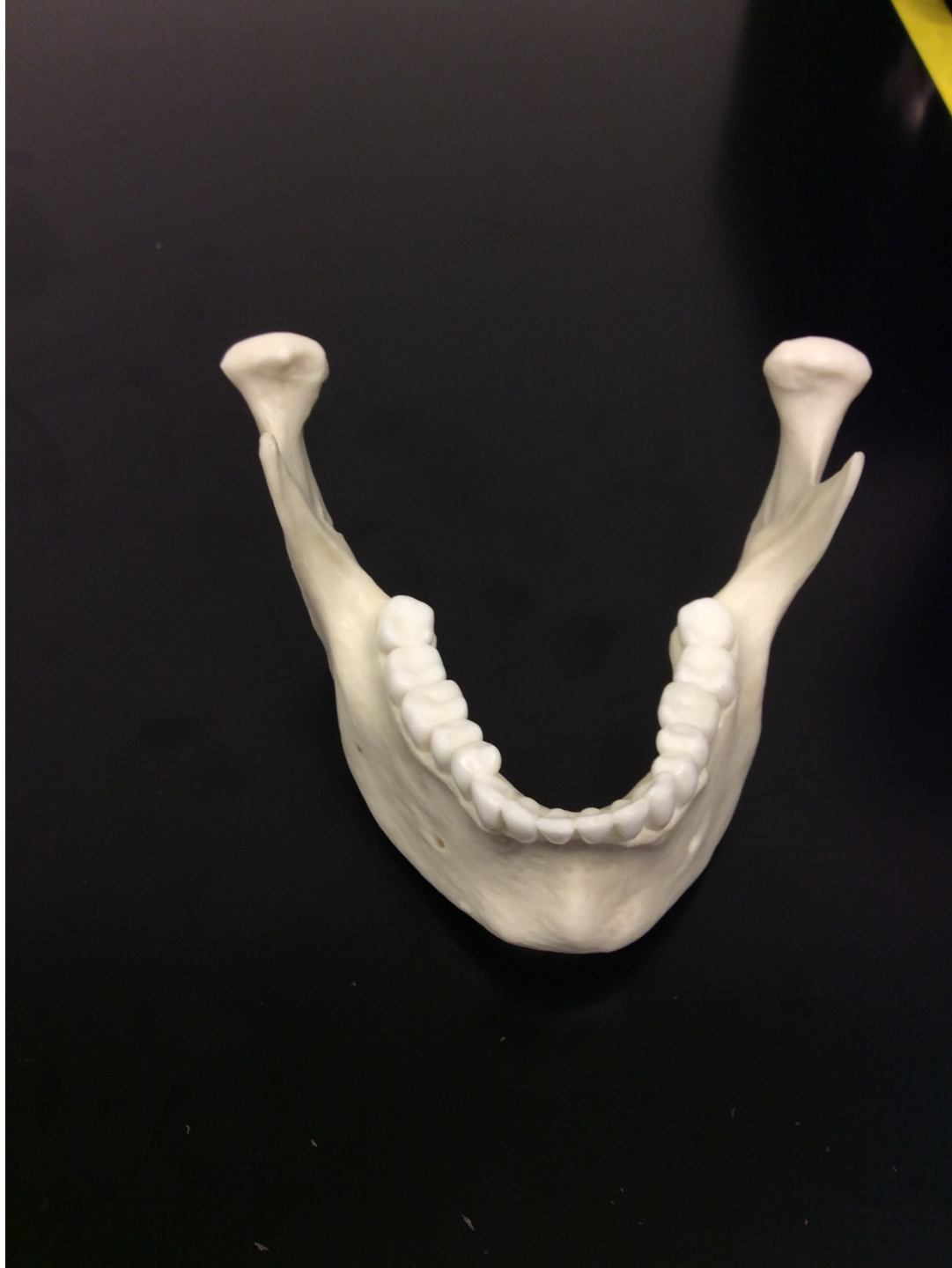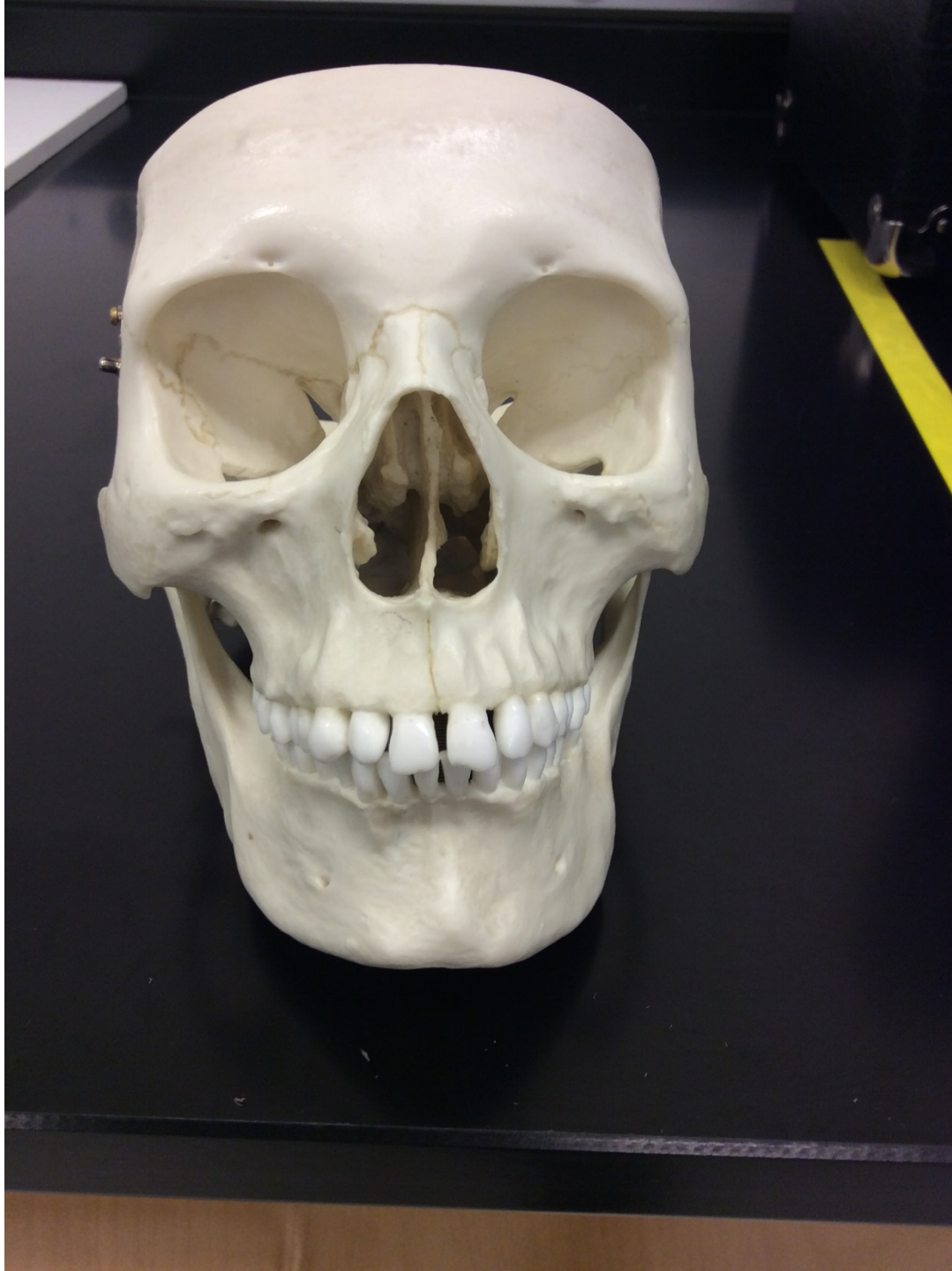**Use the following pictures to help
you practice finding the terms from
the lab term handout on unlabeled
images.**

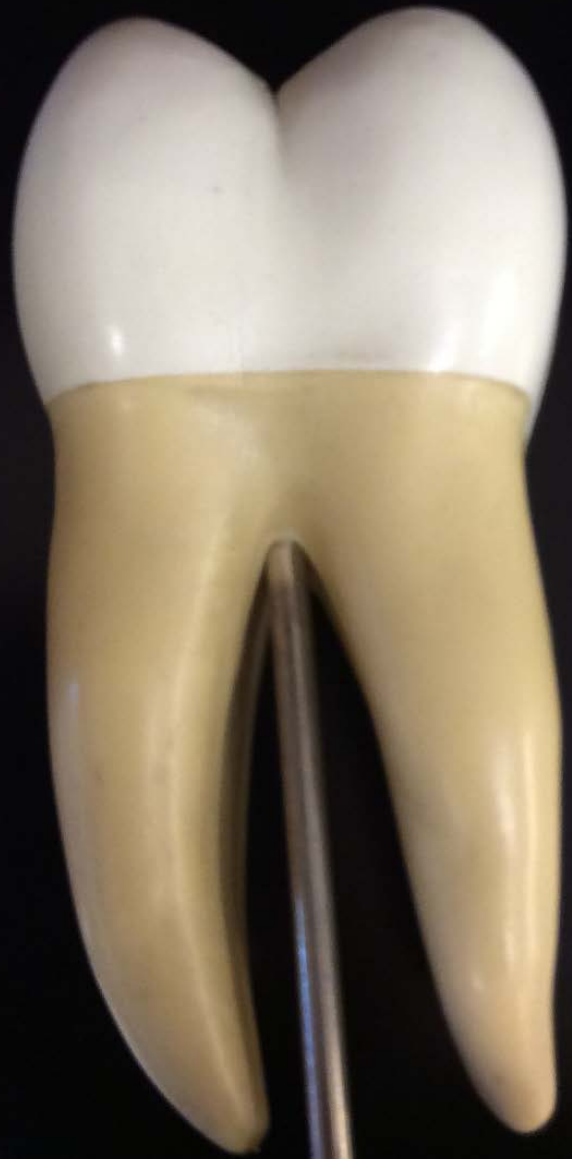- Remember, you won't learn them if you don't take plenty of time to practice on pictures with NO labels (including no labels for what type of slide it is on histology pictures)!
- Also, be sure to mix up the order once you get comfortable with the unlabeled slides.
- Over the weekend, once you are feeling confident with the pictures here, do the histology quizzes in PAL (from the Pearson website) to get practice with new pictures that you haven't seen.

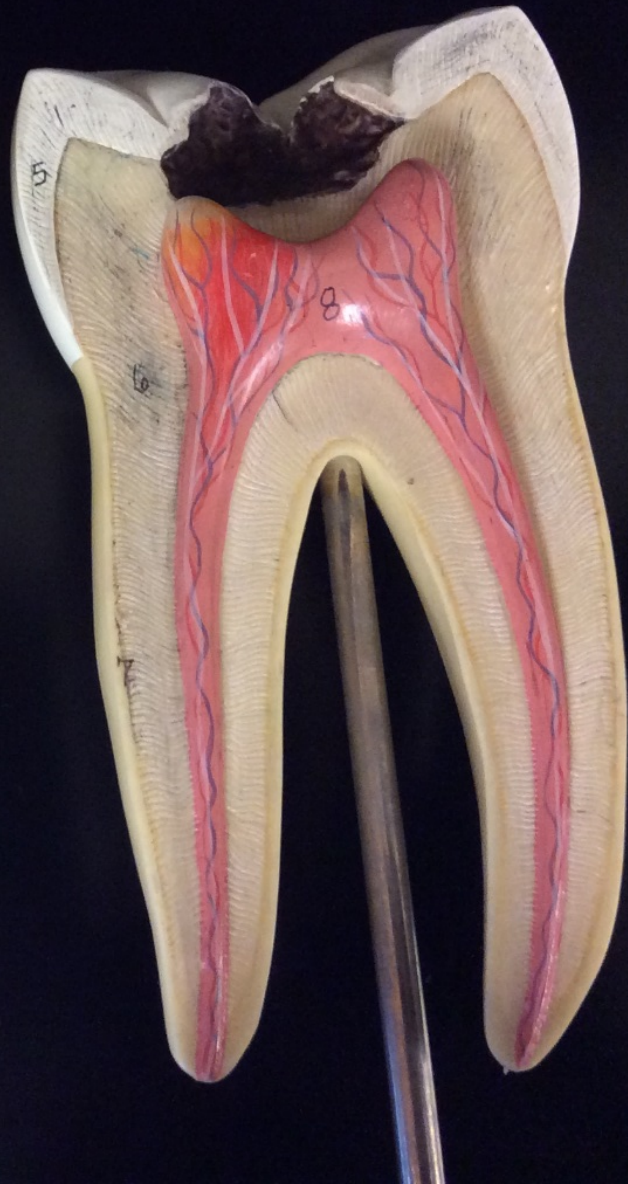
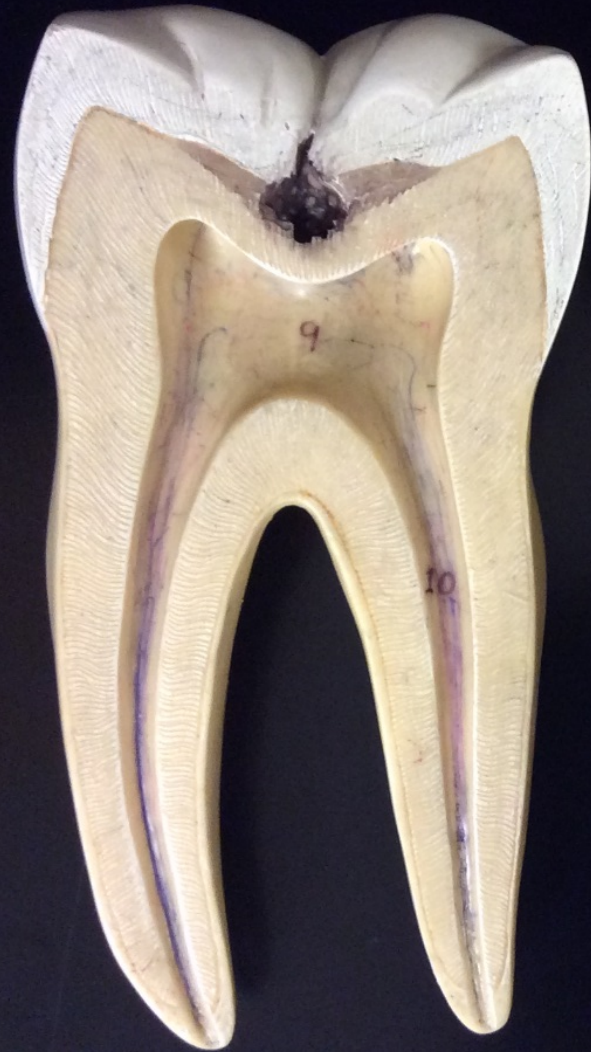


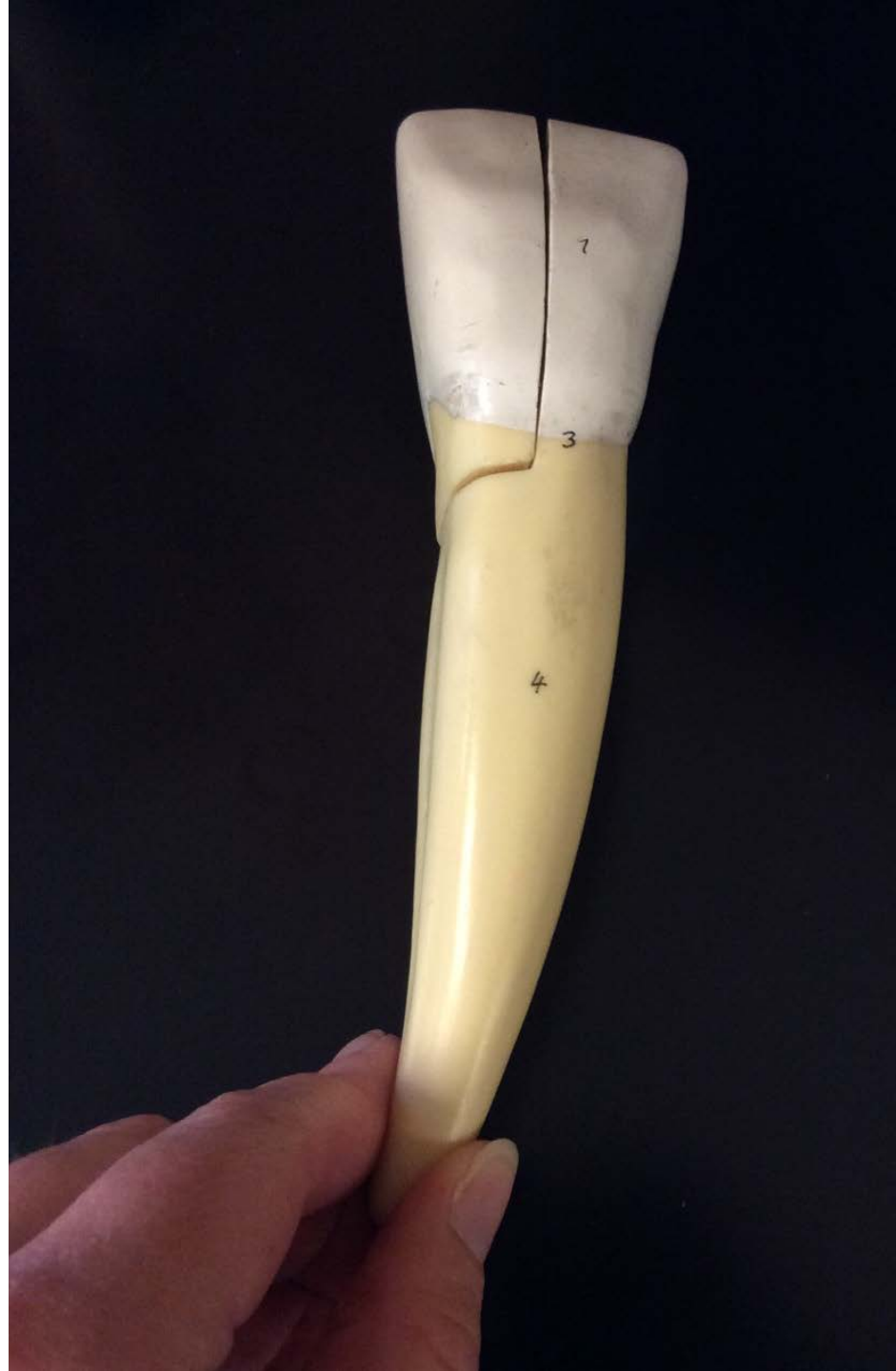



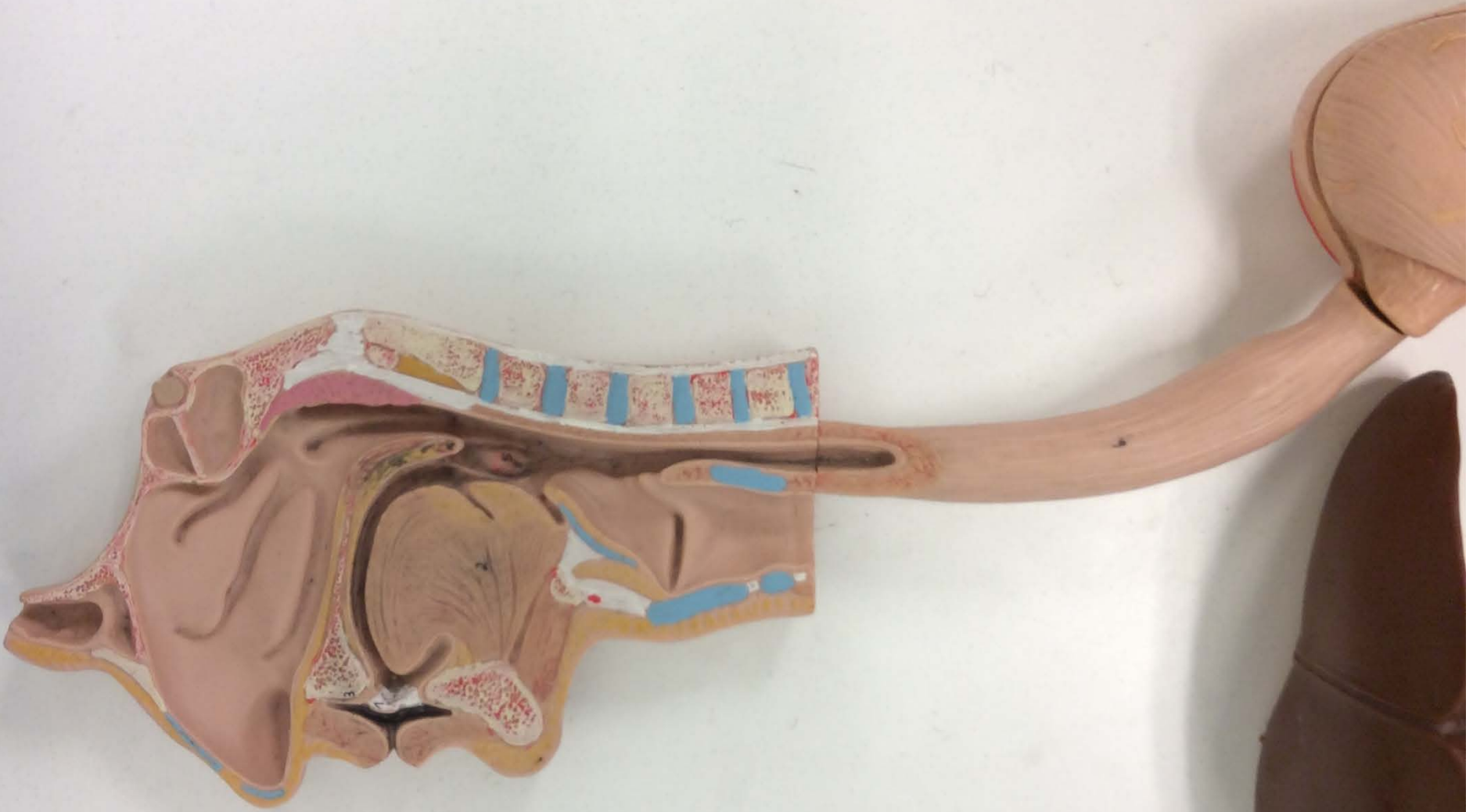





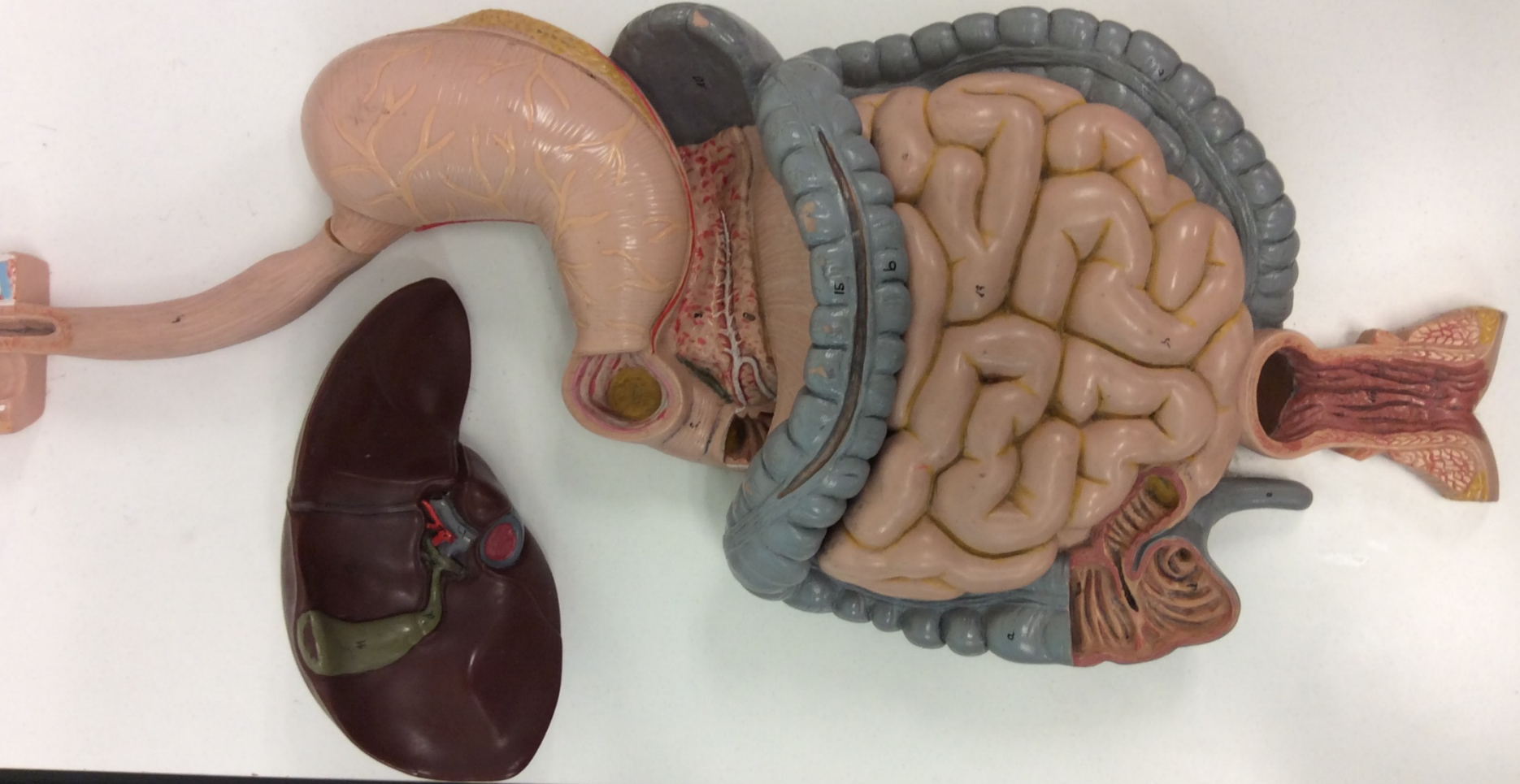




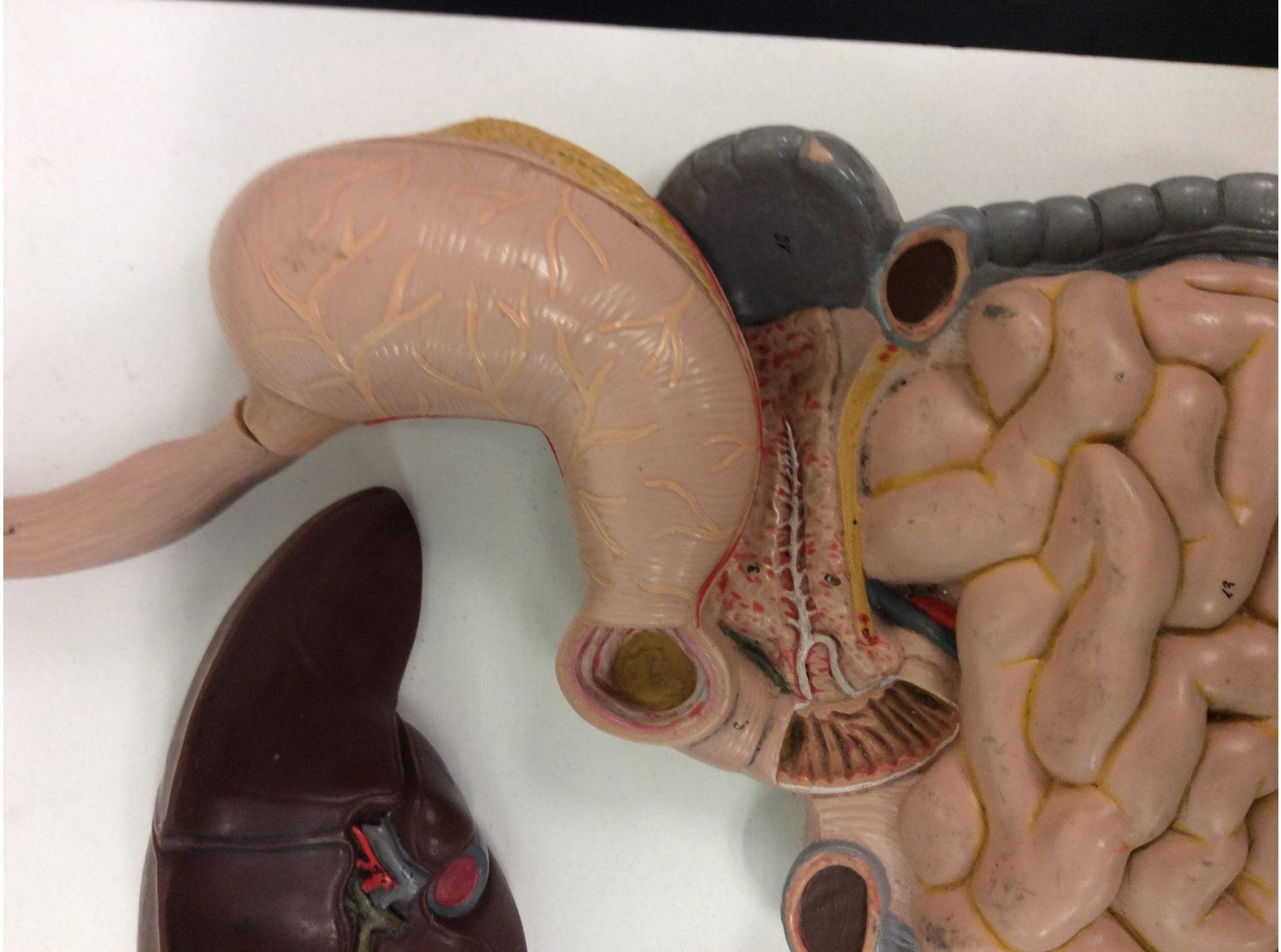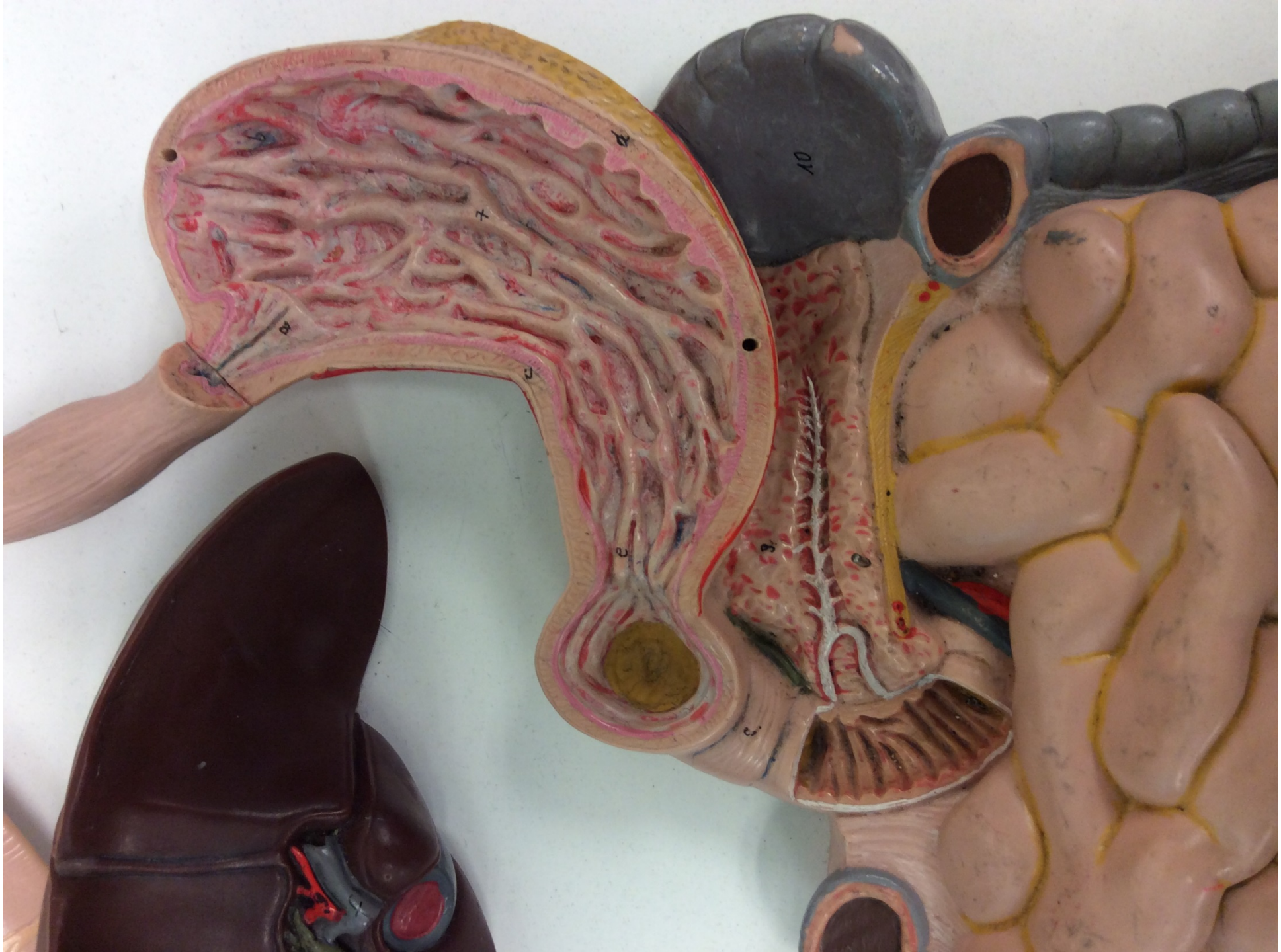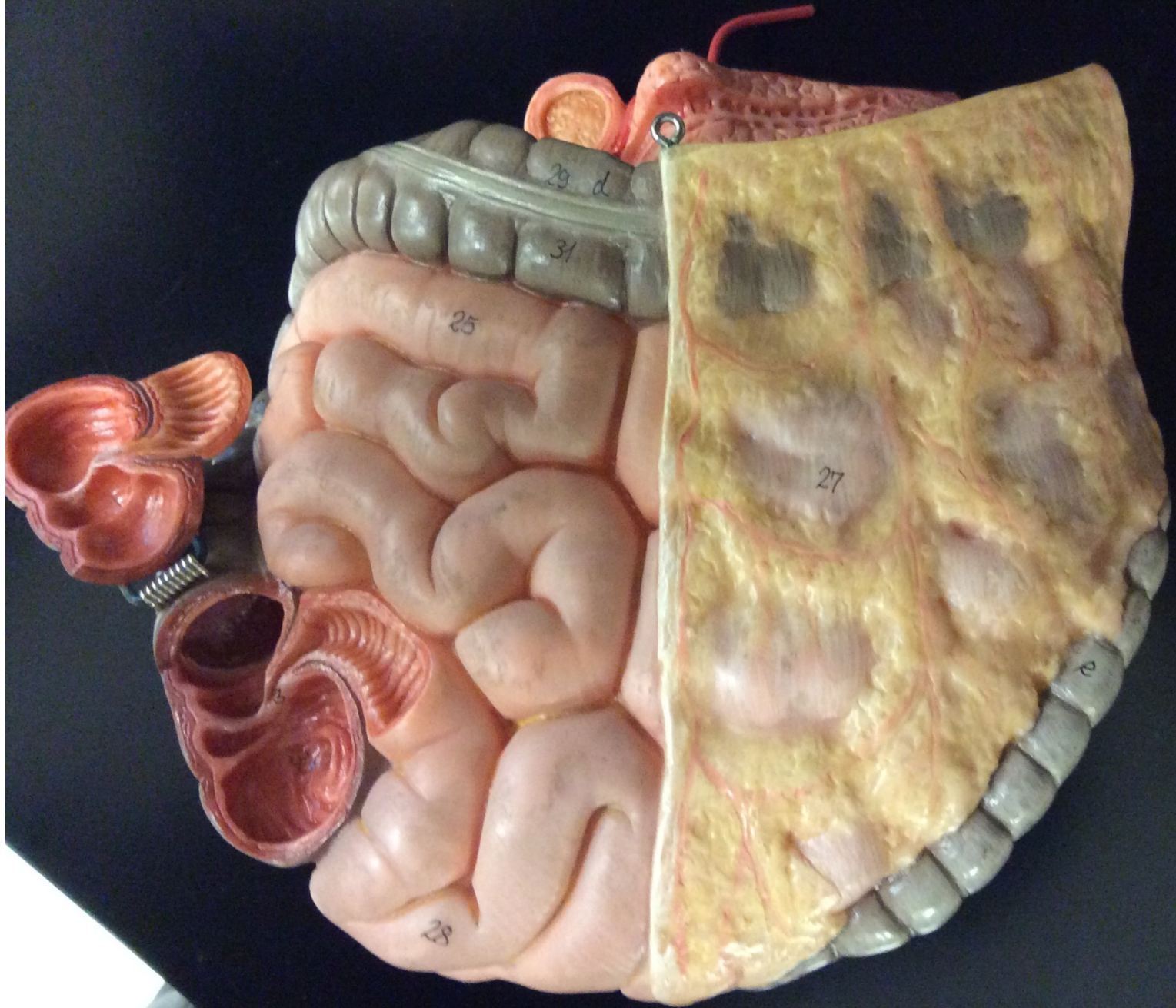


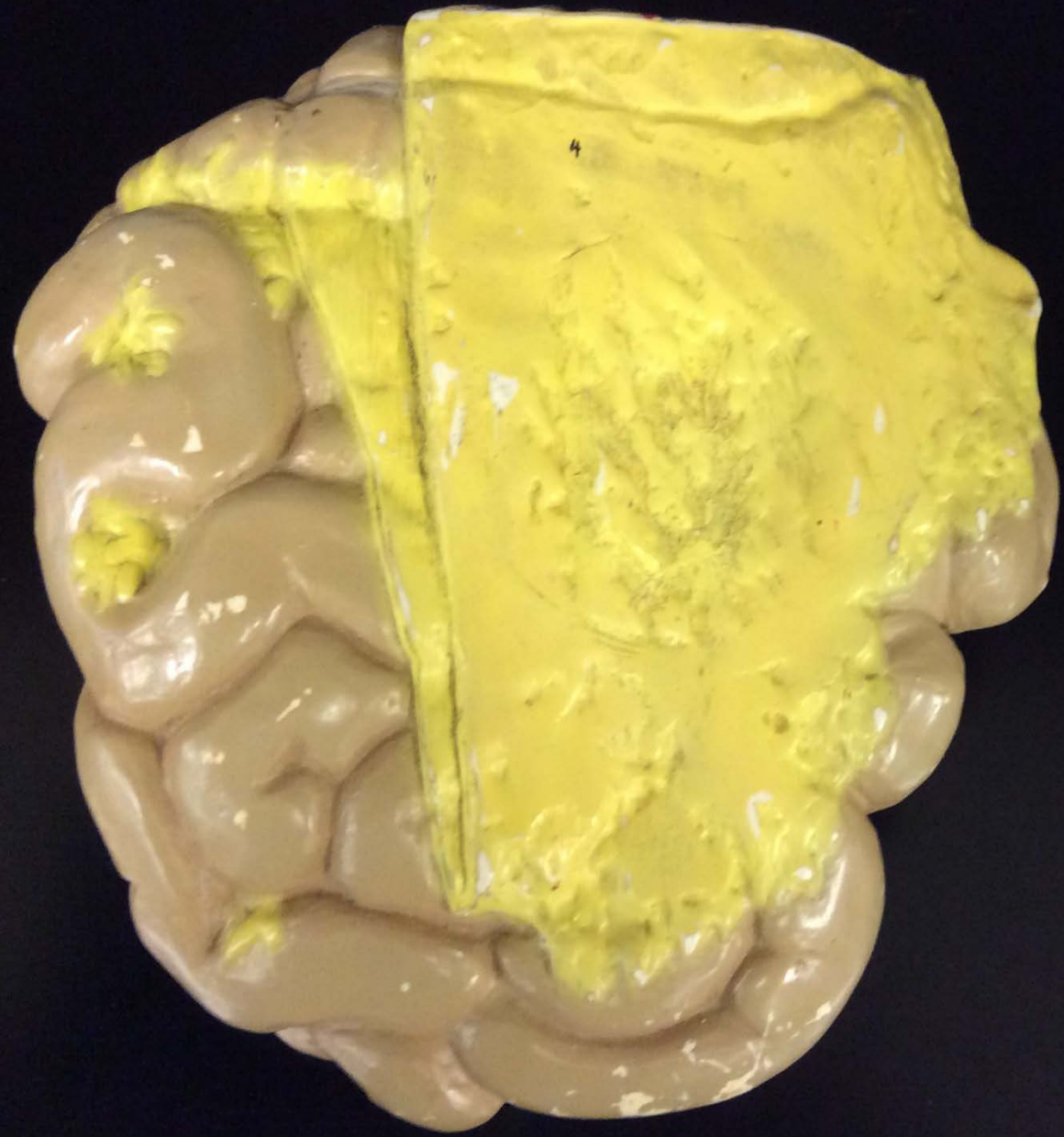


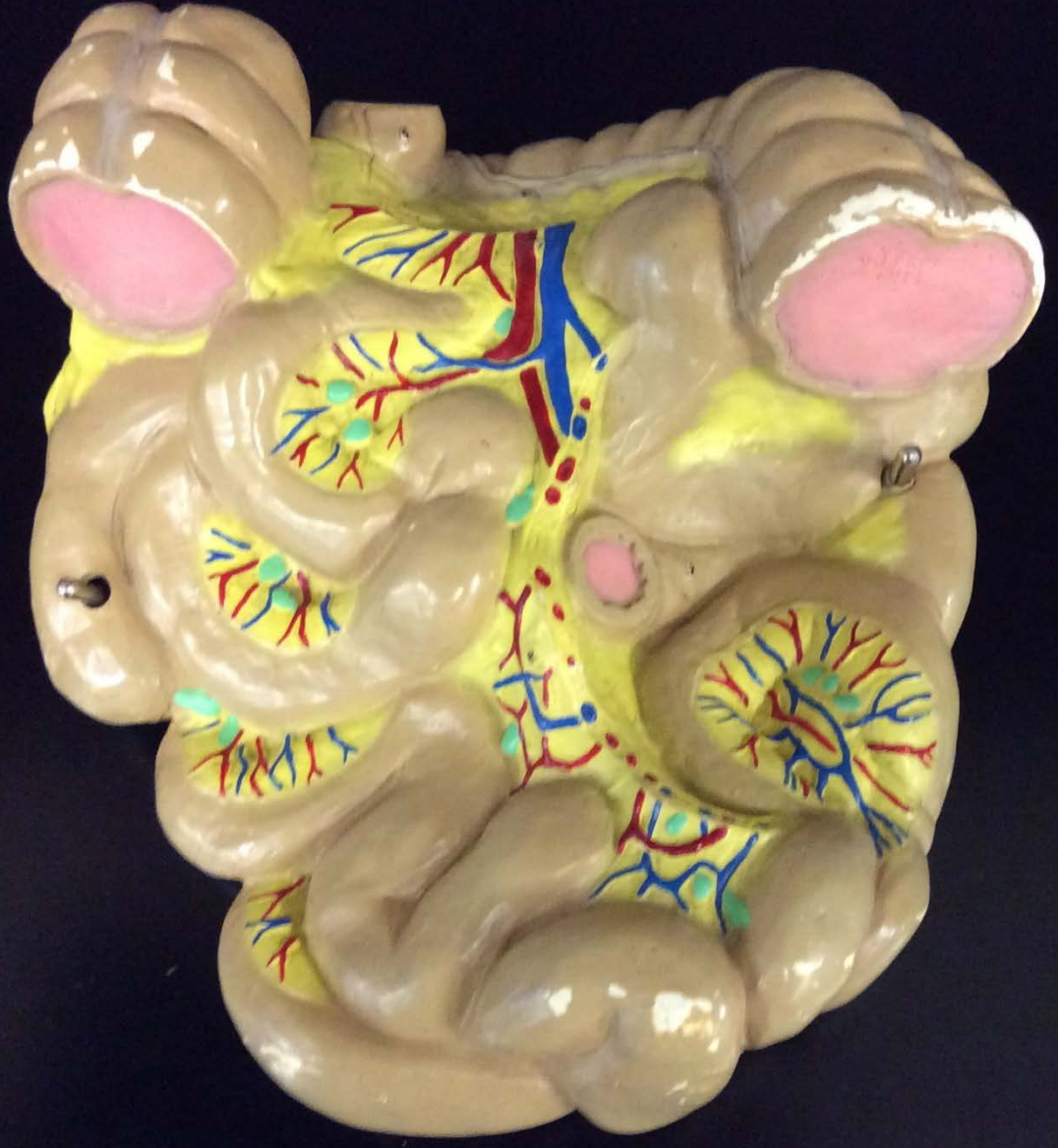11213

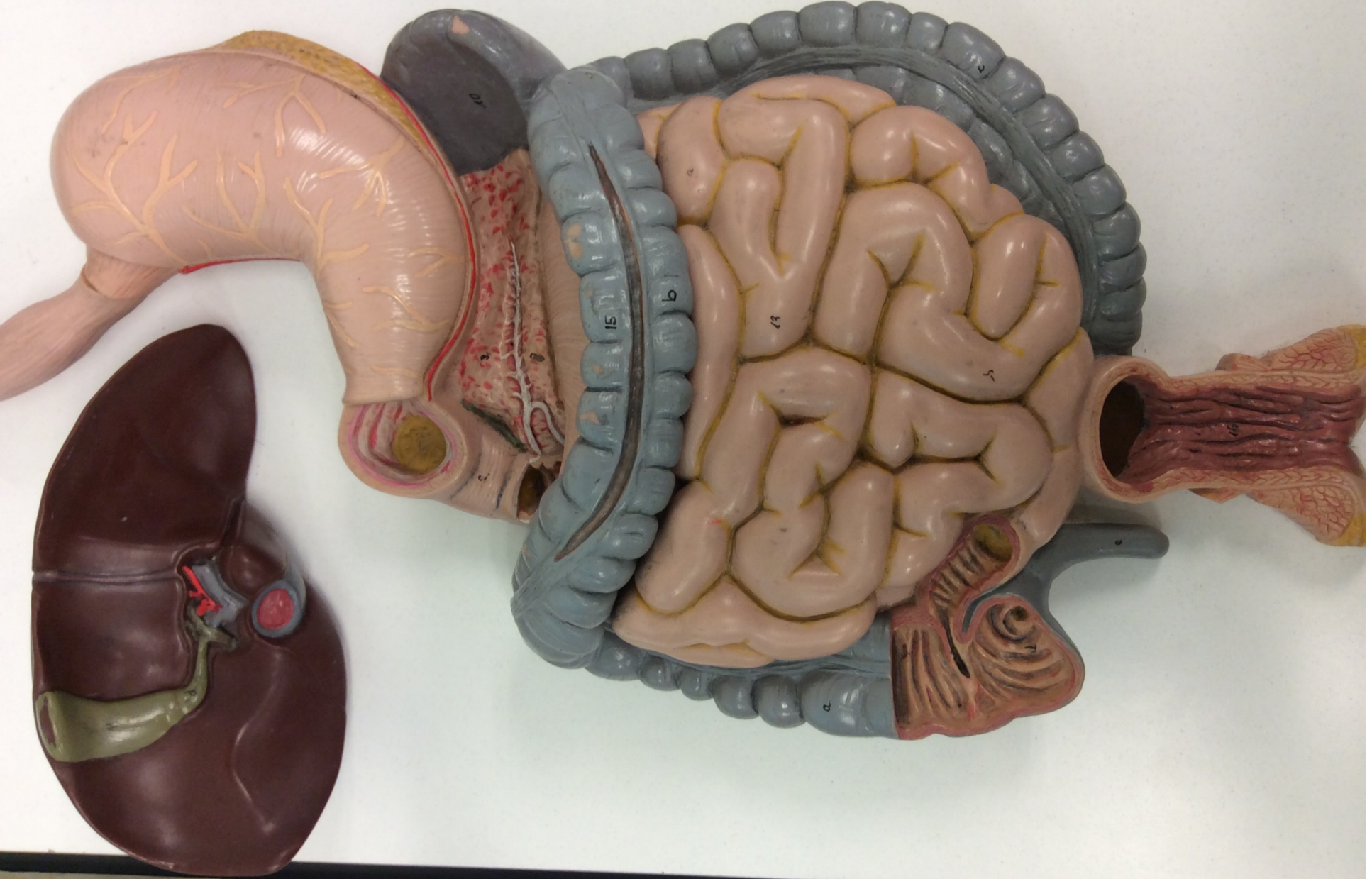



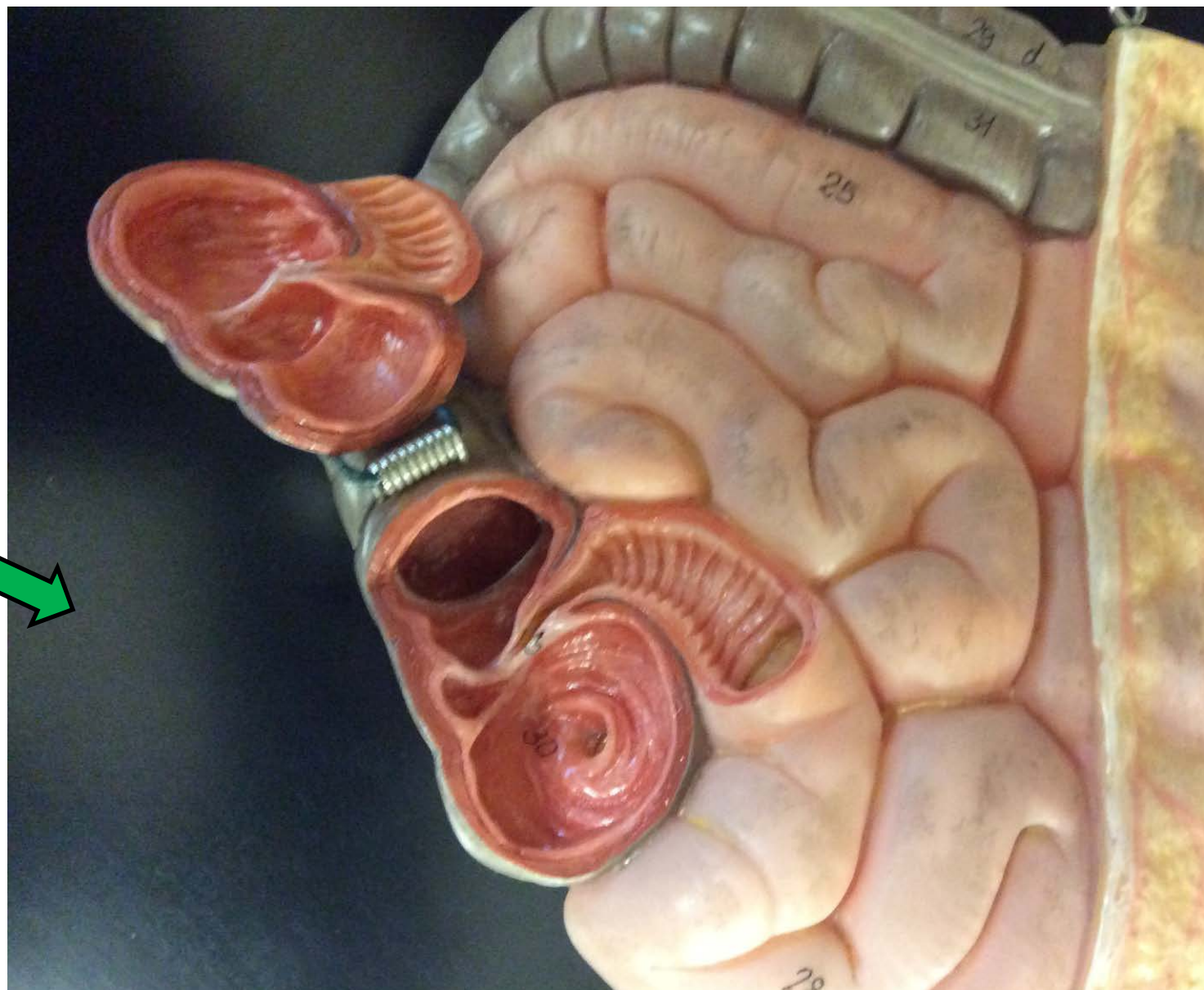
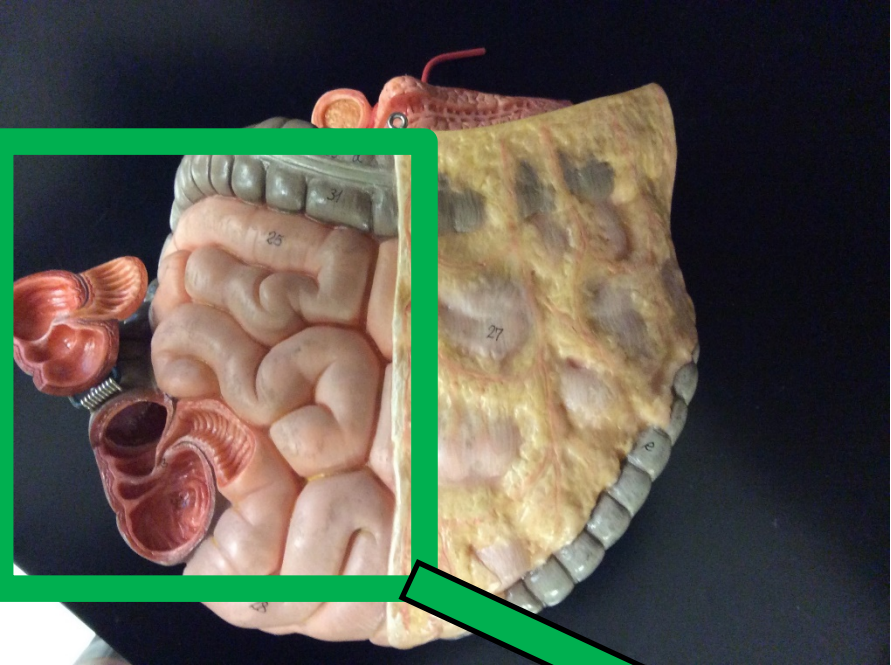




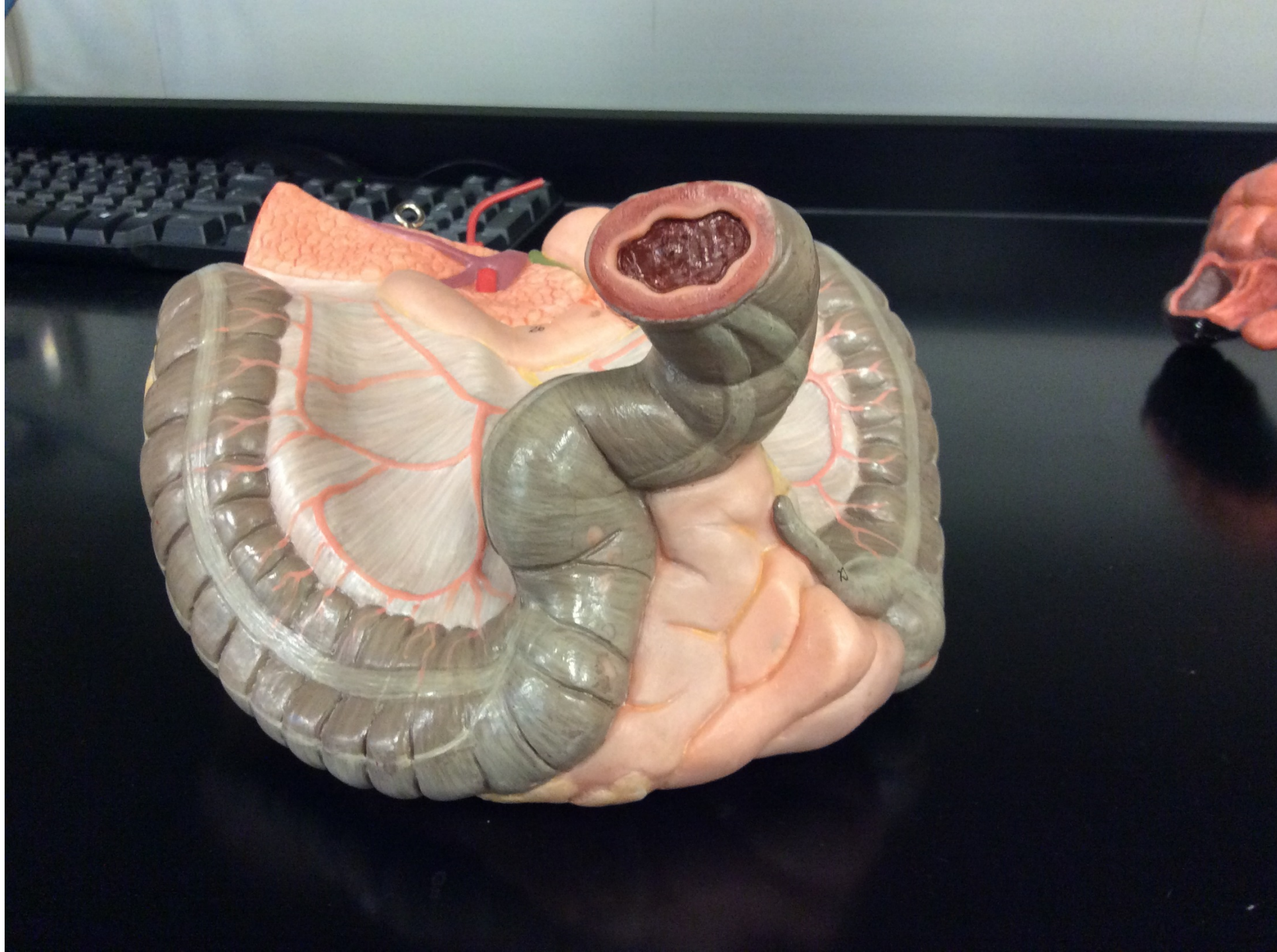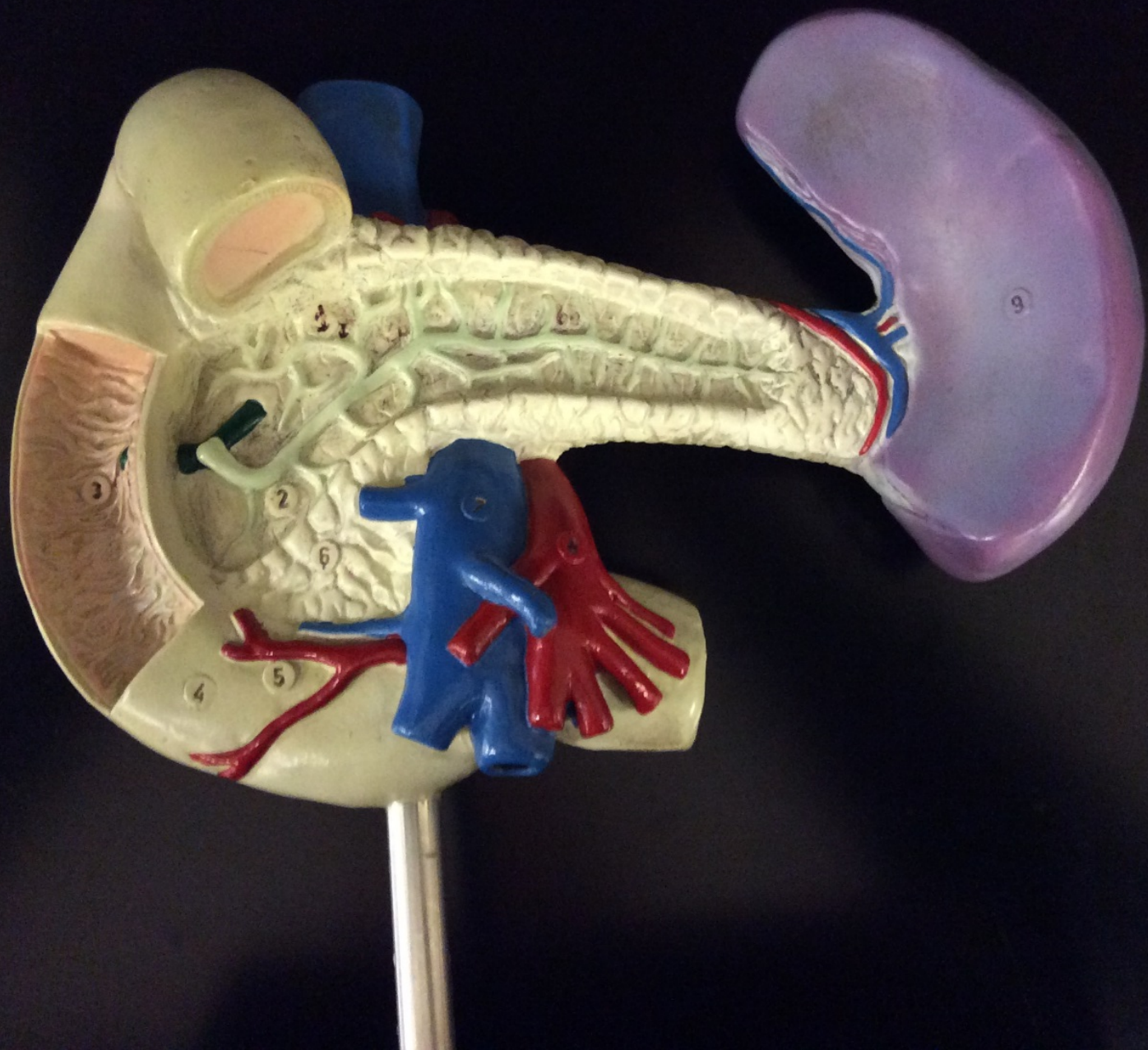


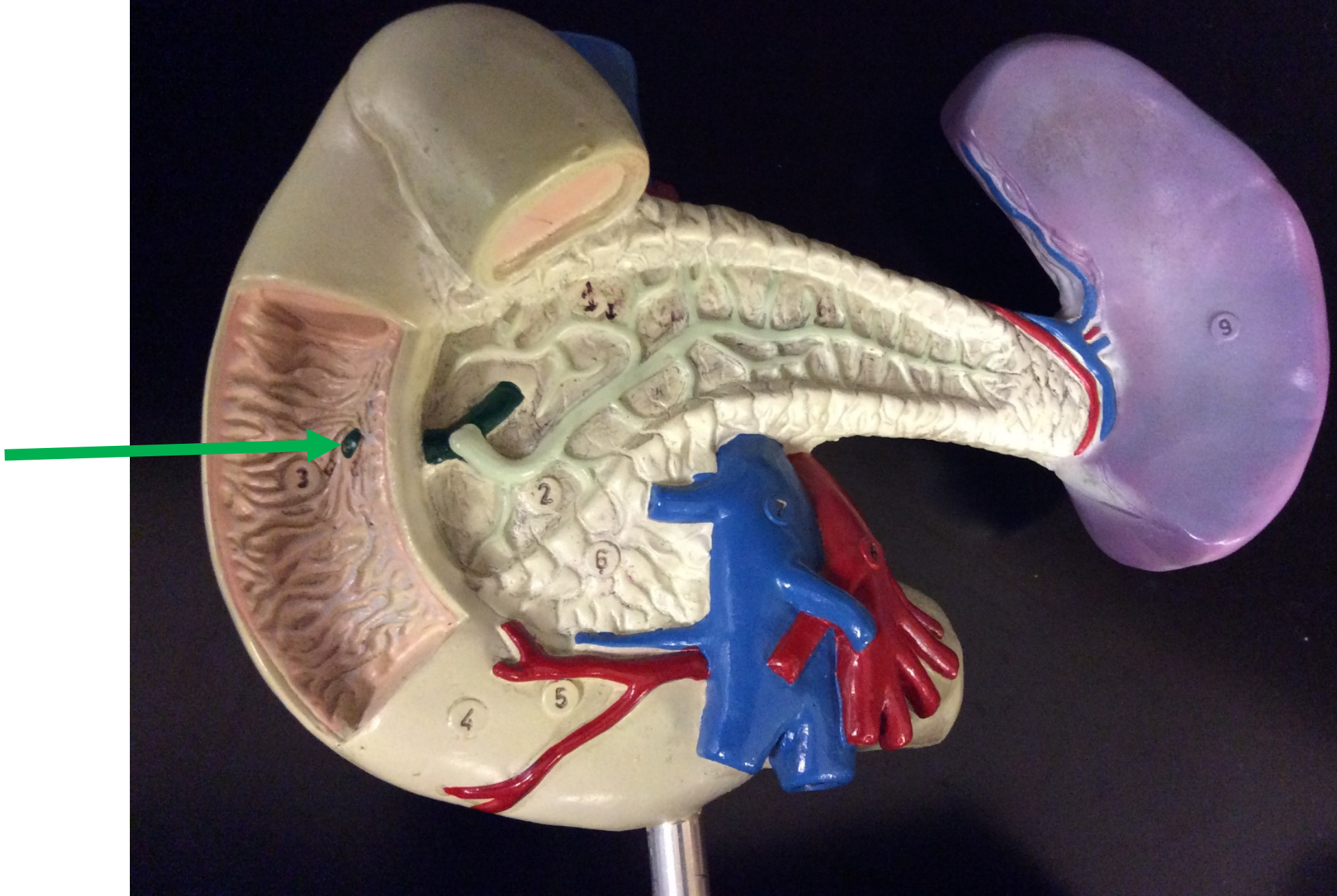


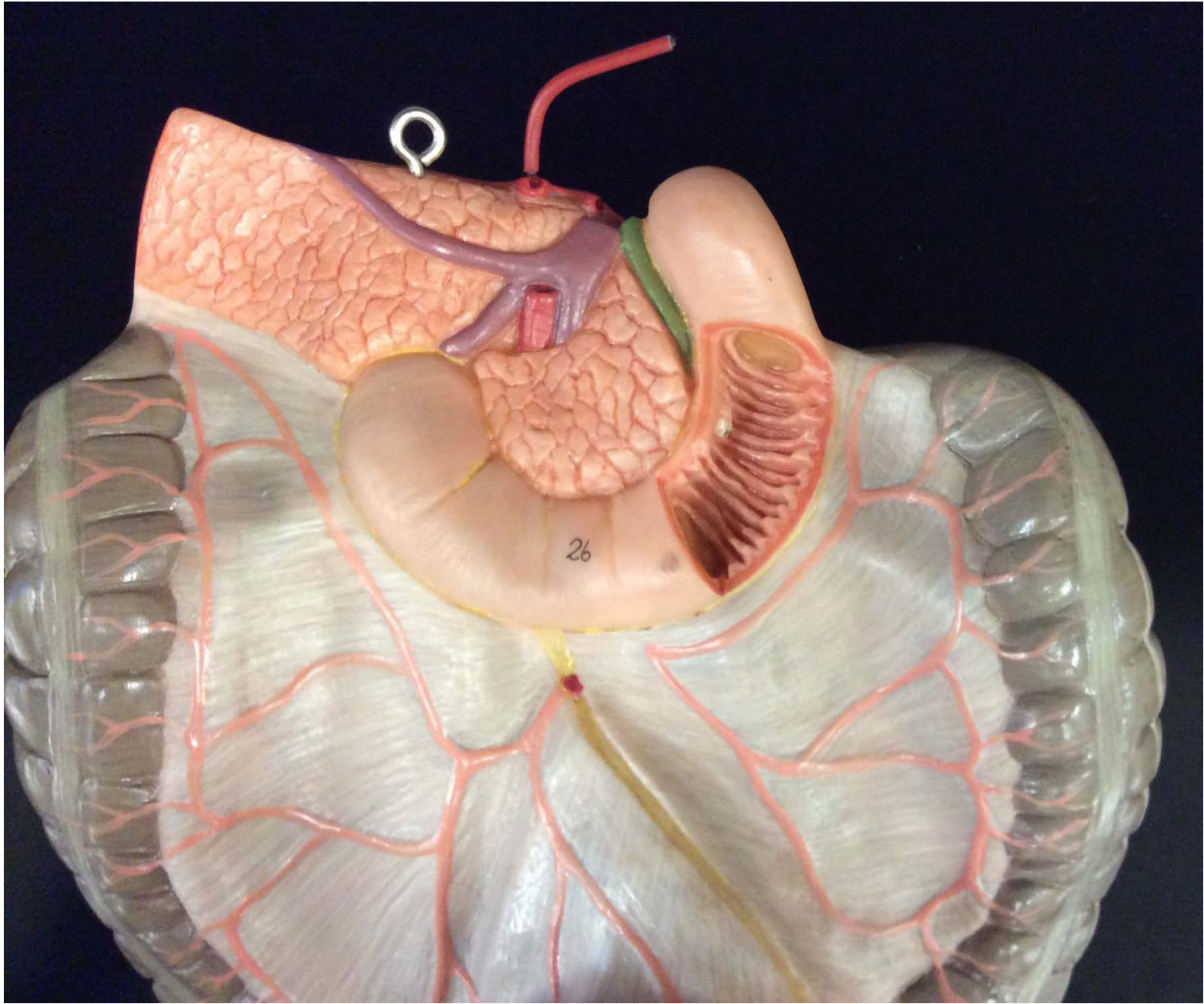


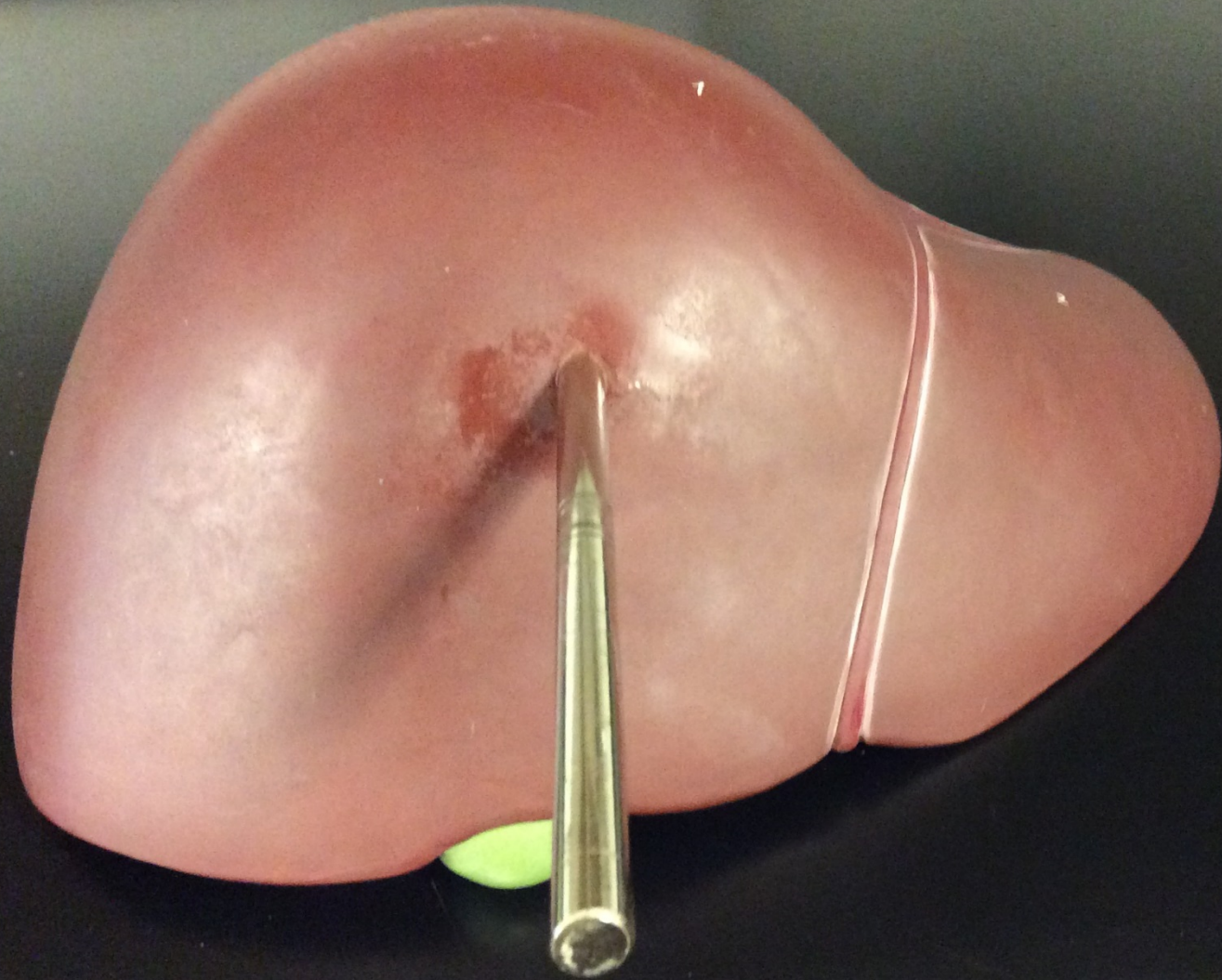


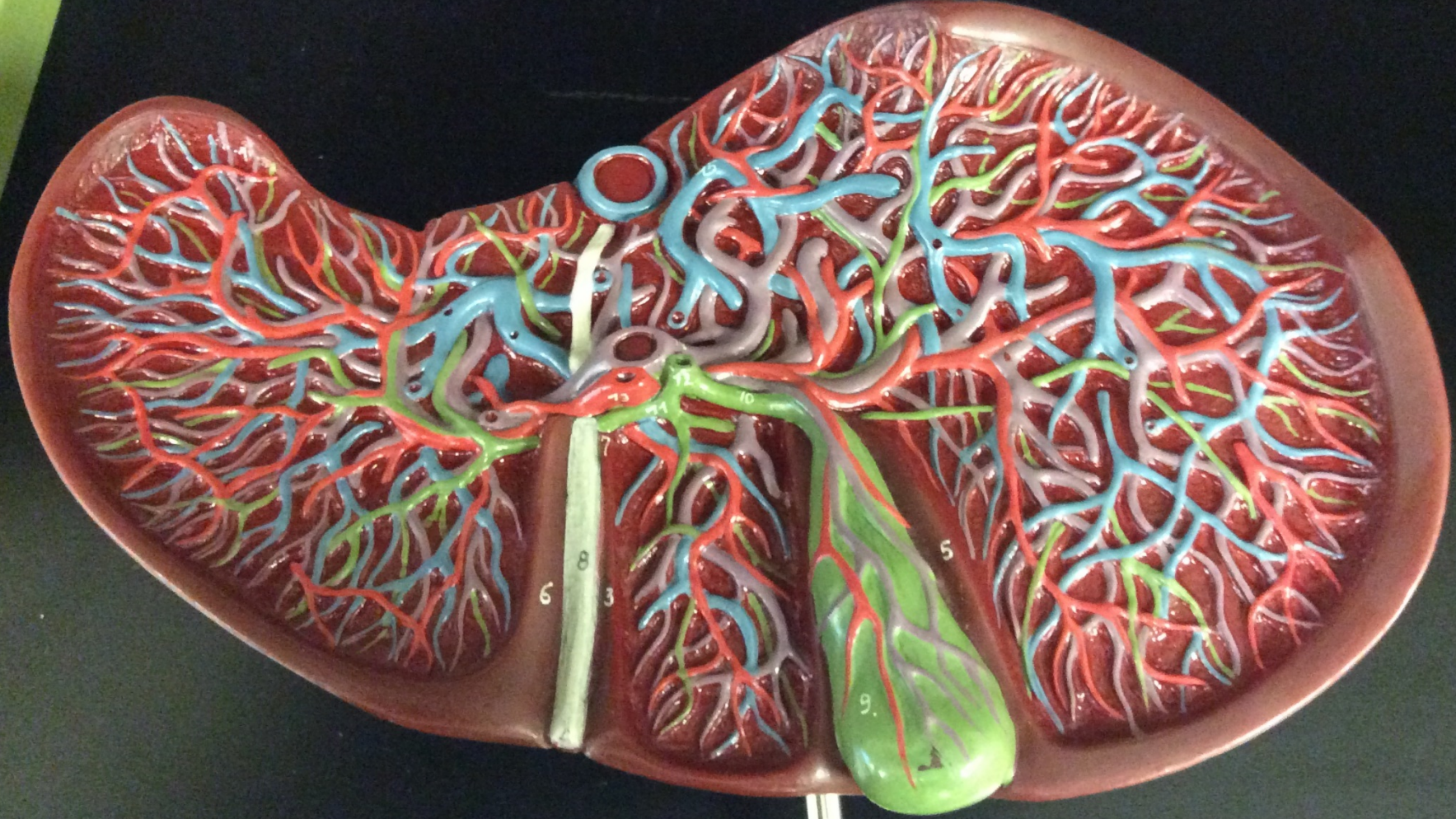


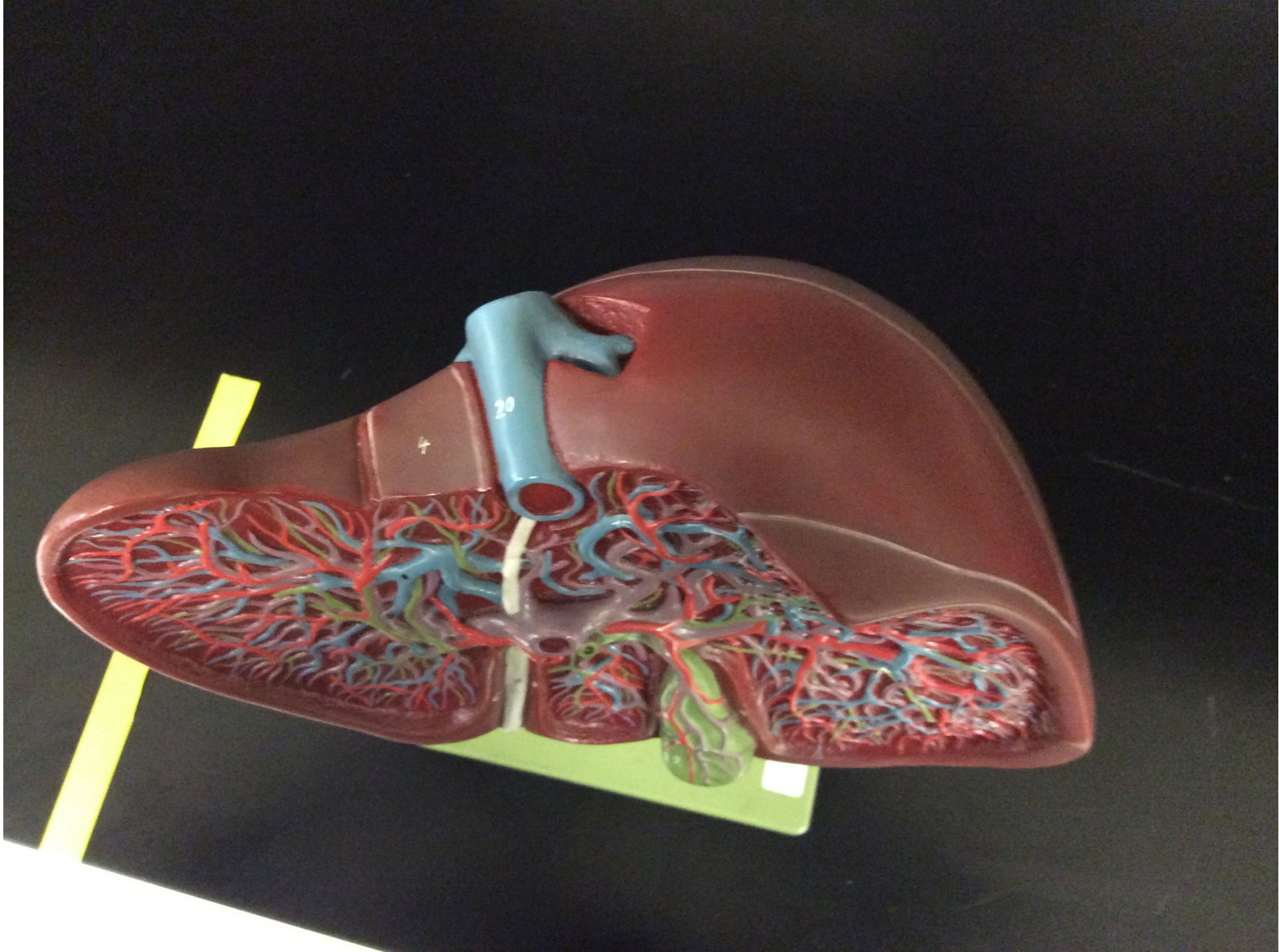


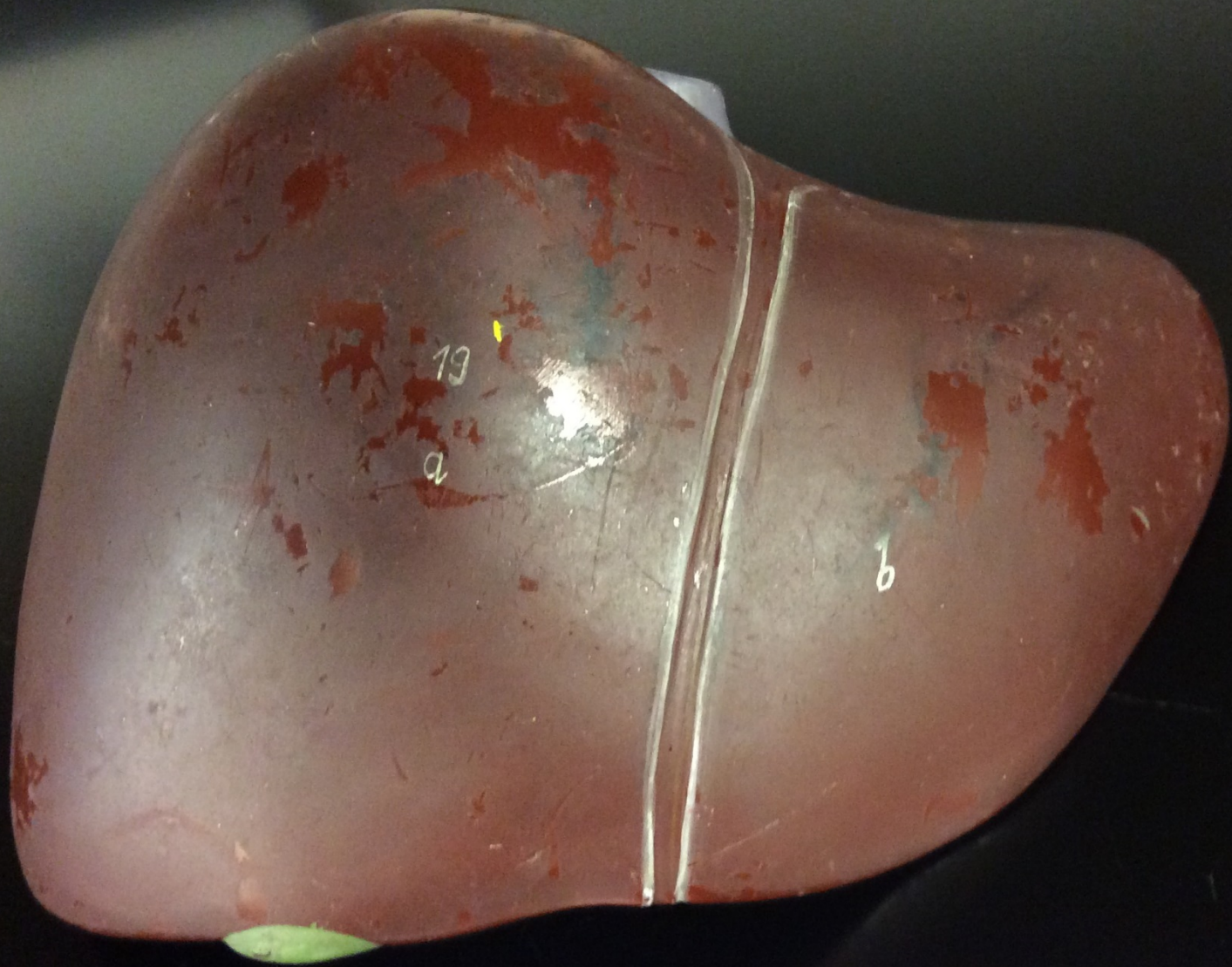





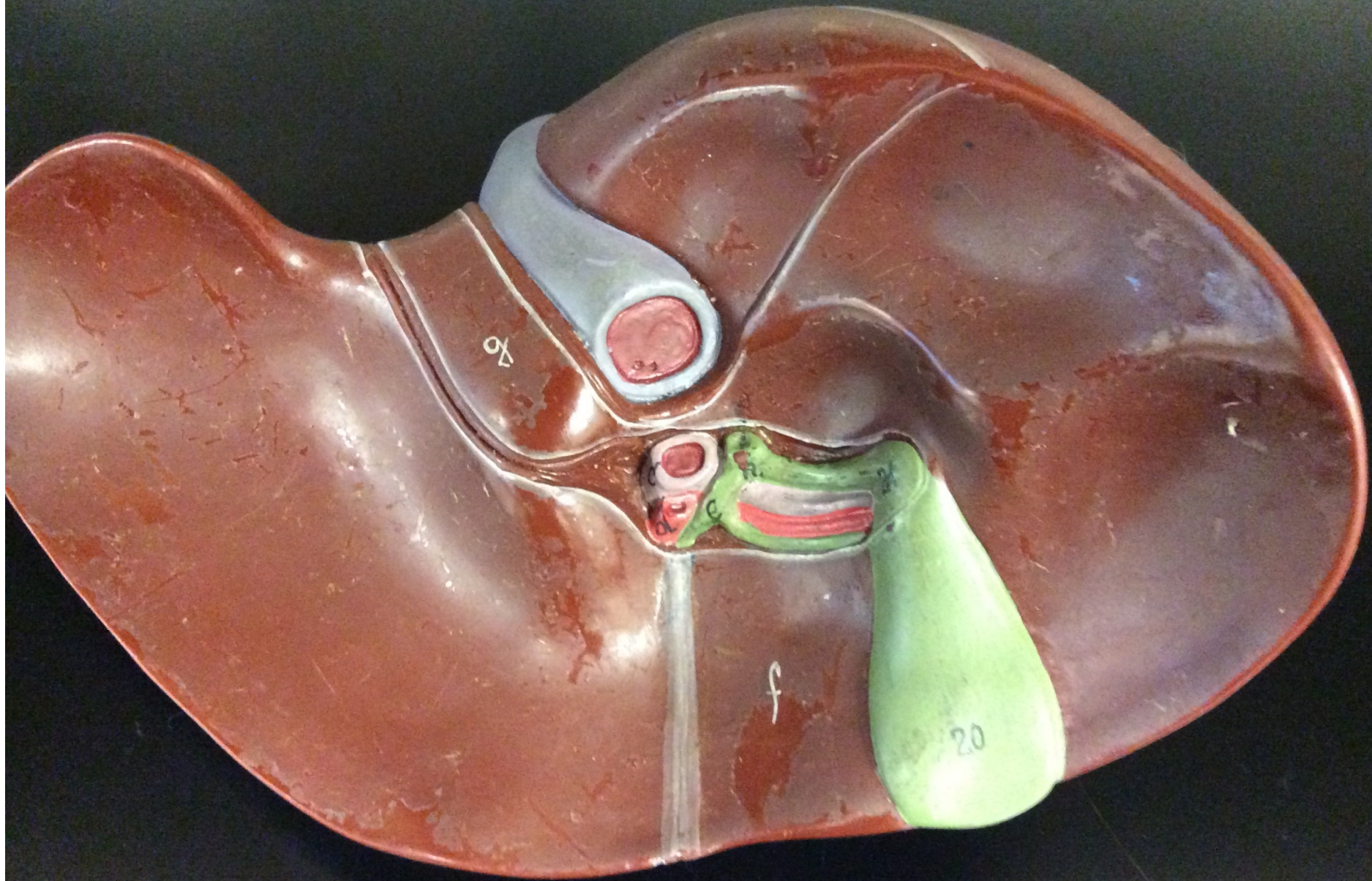






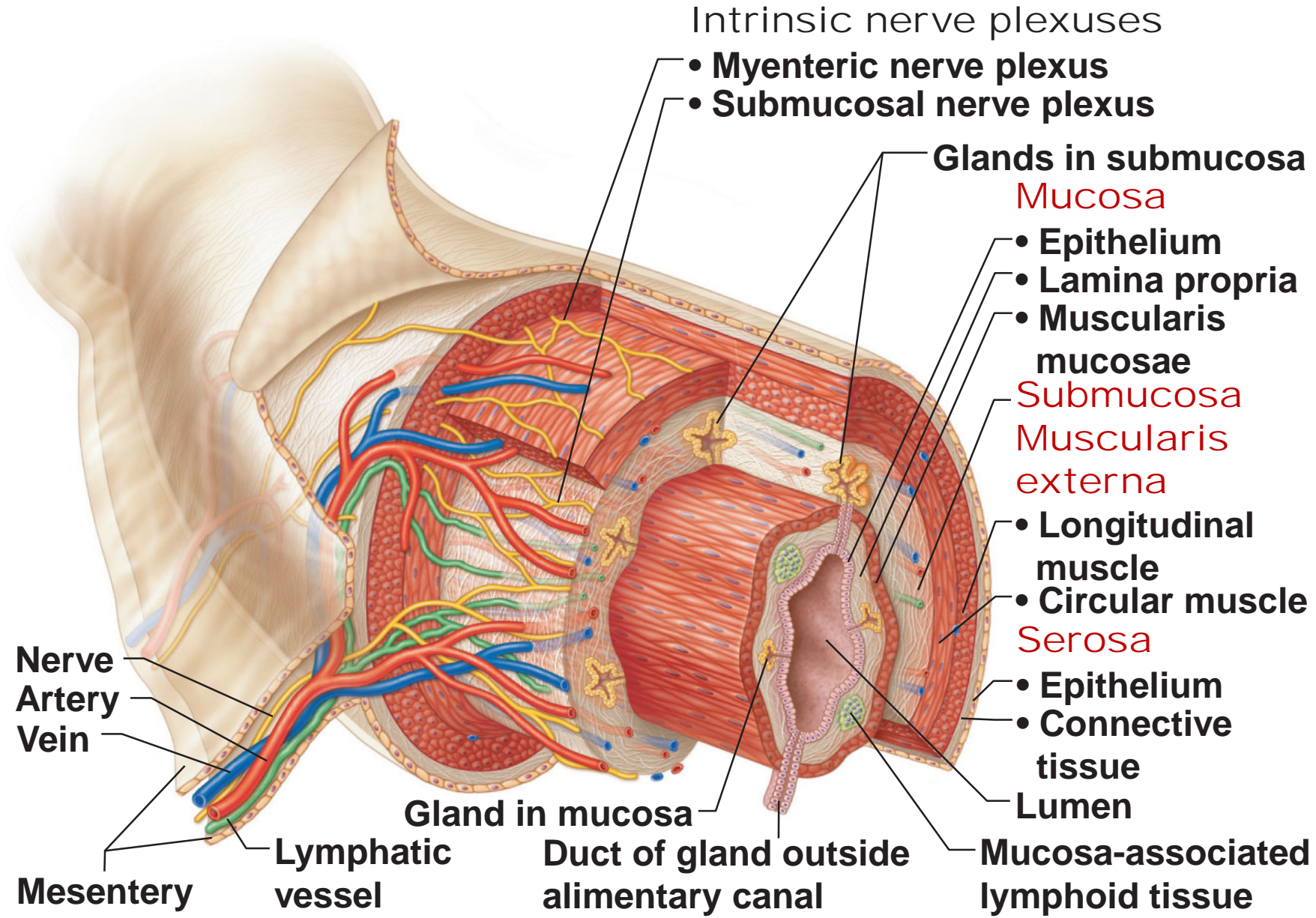


Digestive Histology

Use the following pictures to help
you identify terms from the lab
term handout.

***You always only need to know the terms listed in the lab term handout!

Another good resource for histology is the Olexik website:
http://faculty.montgomerycollege.edu/wolexik/205_histology_page.htm



Intrinsic nerve plexuses

- Myenteric nerve plexus
- Submucosal nerve plexus

Glands in submucosa

Mucosa

- Epithelium
- Lamina propria
- Muscularis mucosae

Submucosa

Muscularis externa

- Longitudinal muscle
- Circular muscle

Serosa

- Epithelium
- Connective tissue

Lumen

Mucosa-associated lymphoid tissue

Nerve
Artery
Vein

Mesentery

Lymphatic vessel

Gland in mucosa

Duct of gland outside alimentary canal

Esophagus-40x

Lumen

Epithelium

Ducts

B
a
s
e
m
e
n
t
M
e
m
b
r
a
n
e

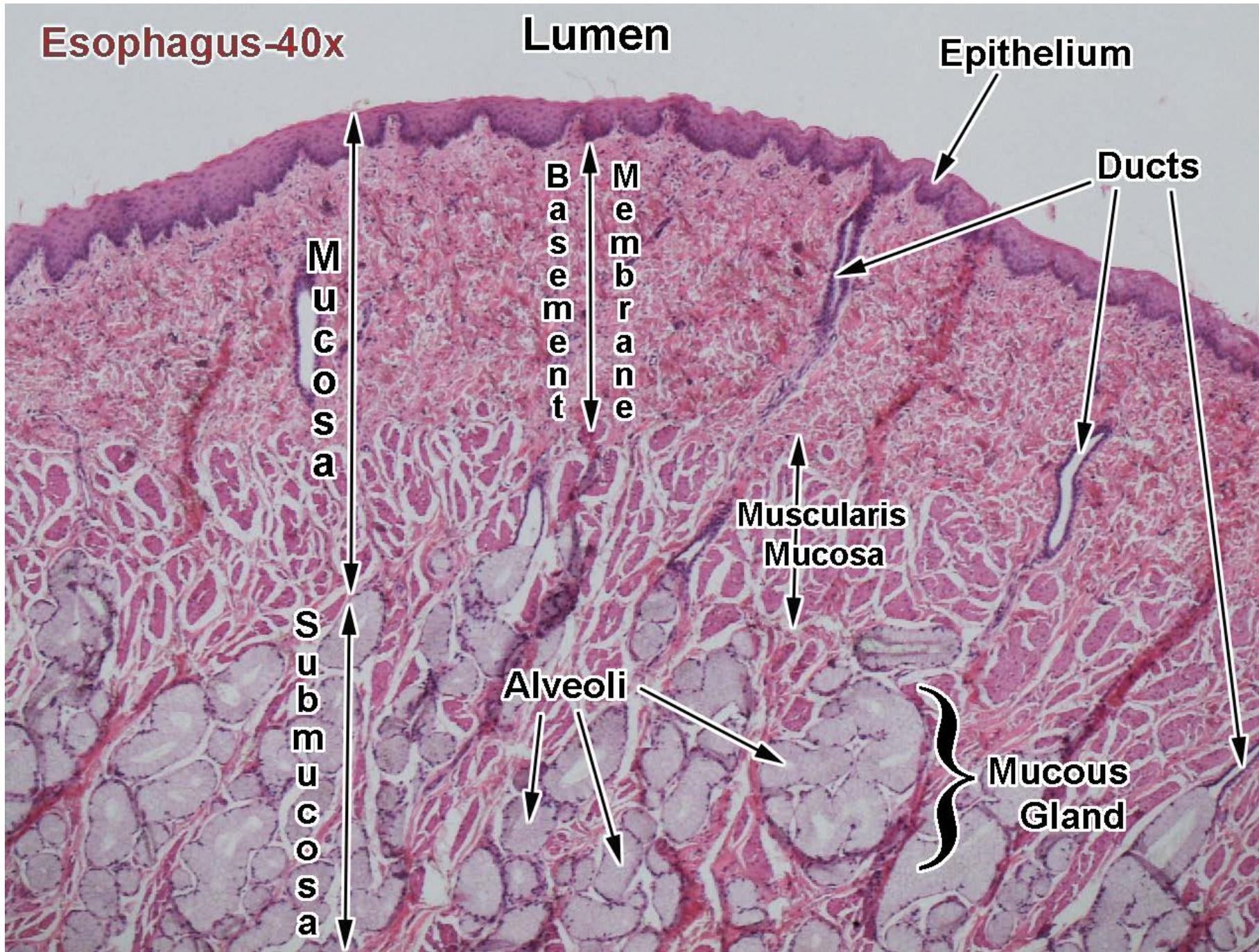
M
u
c
o
s
a

M
u
s
c
u
l
a
r
i
s
M
u
c
o
s
a

S
u
b
m
u
c
o
s
a

Alveoli

Mucous
Gland



Esophagus
Slide
(Inner)

Olexik
Website

Esophagus-40x

Submucosa

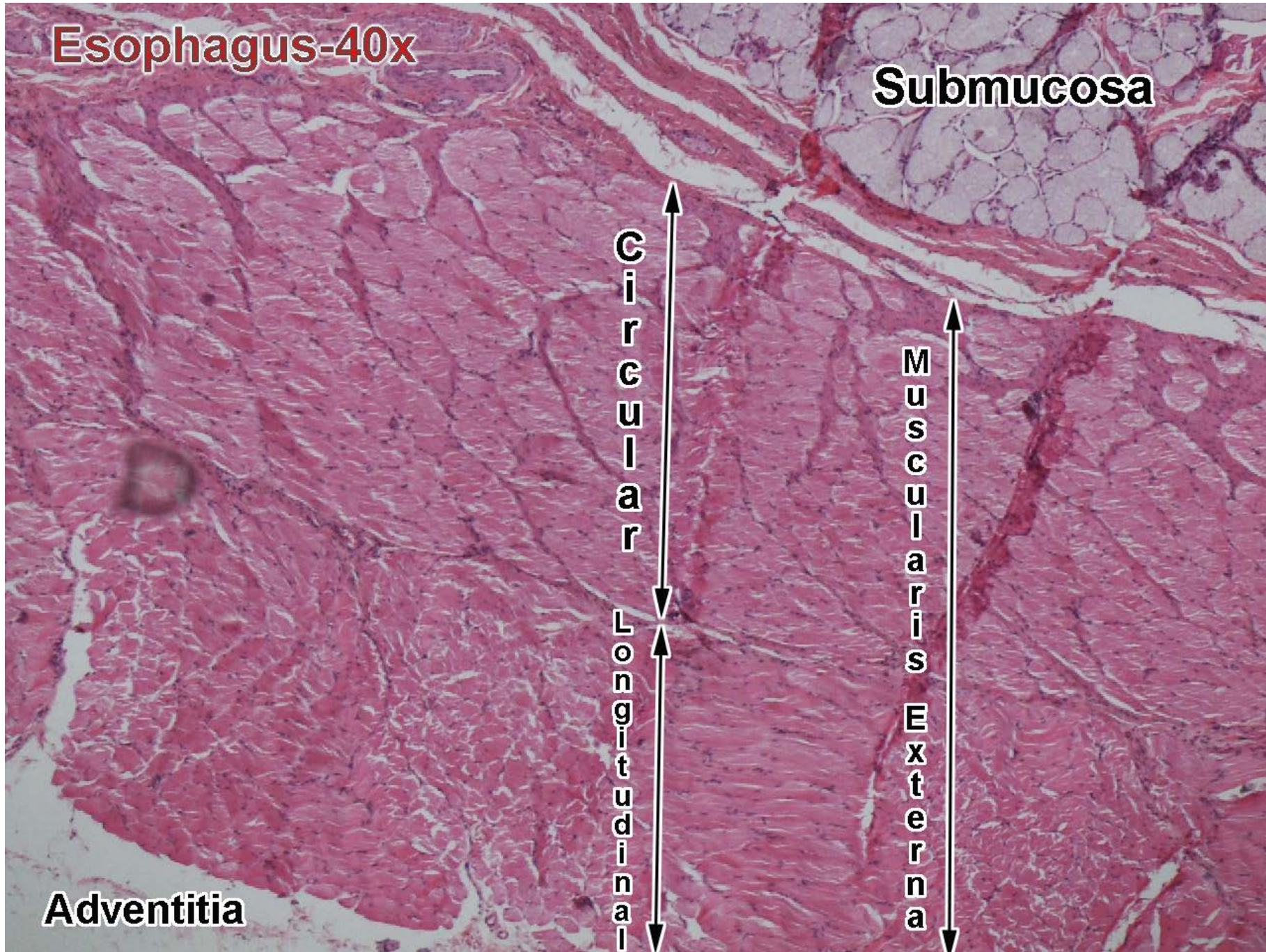
Circular

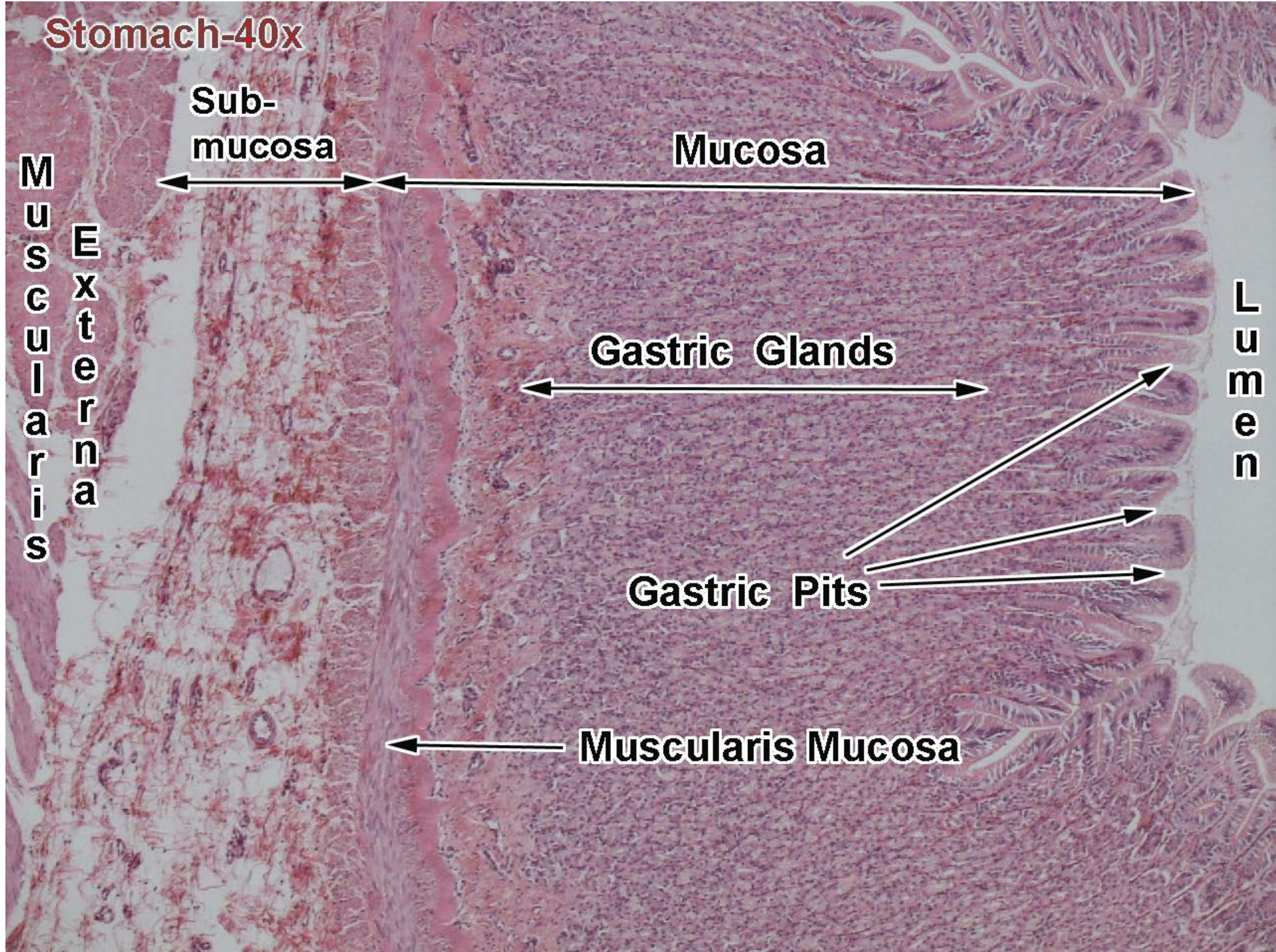
Muscularis Externa

Adventitia

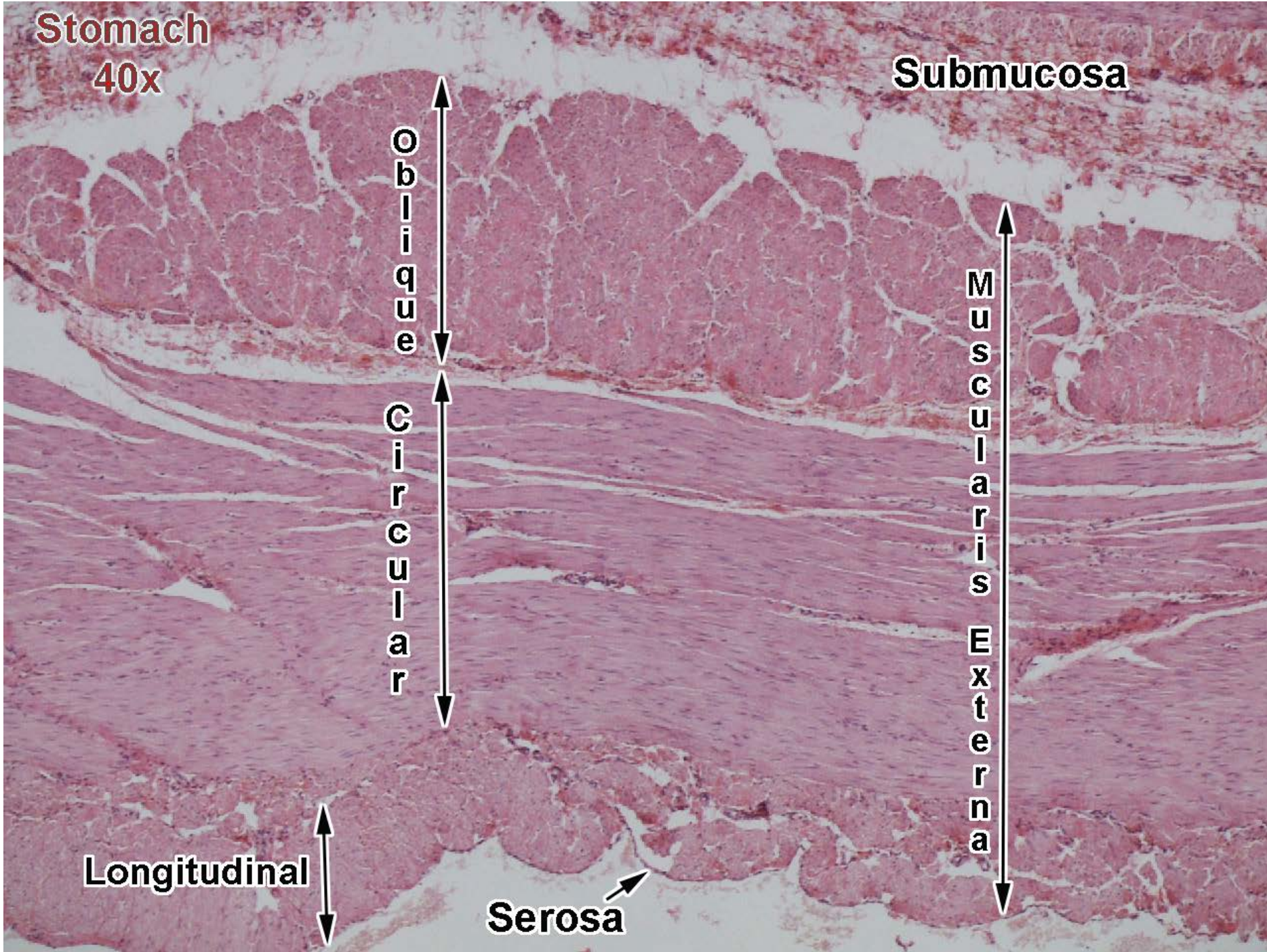
**Esophagus
Slide
(Outer)**

**Olexik
Website**





**Stomach
Slide
(Inner)**



Stomach
Slide
(Outer)

Stomach-200x

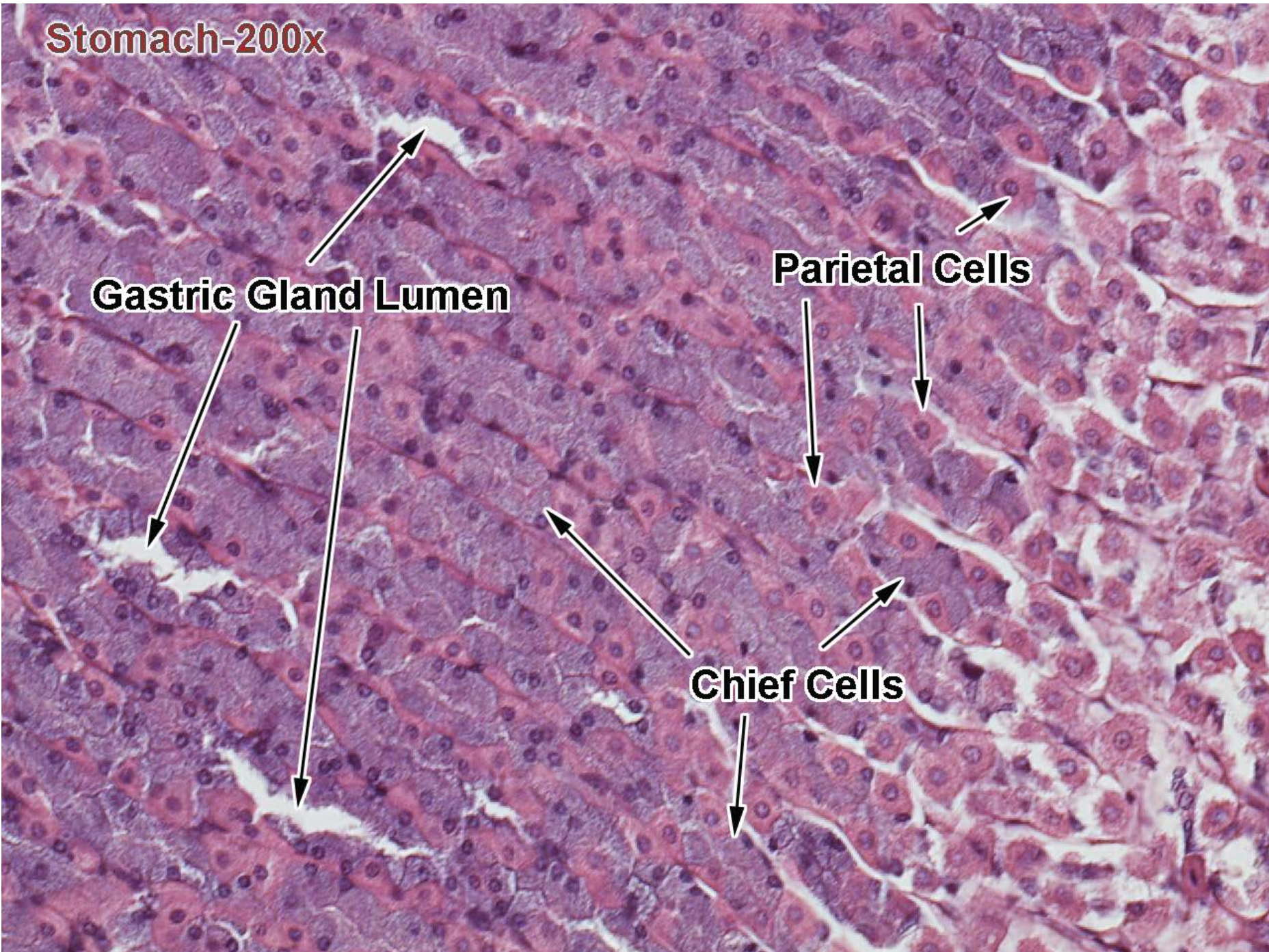
Gastric Gland Lumen

Parietal Cells

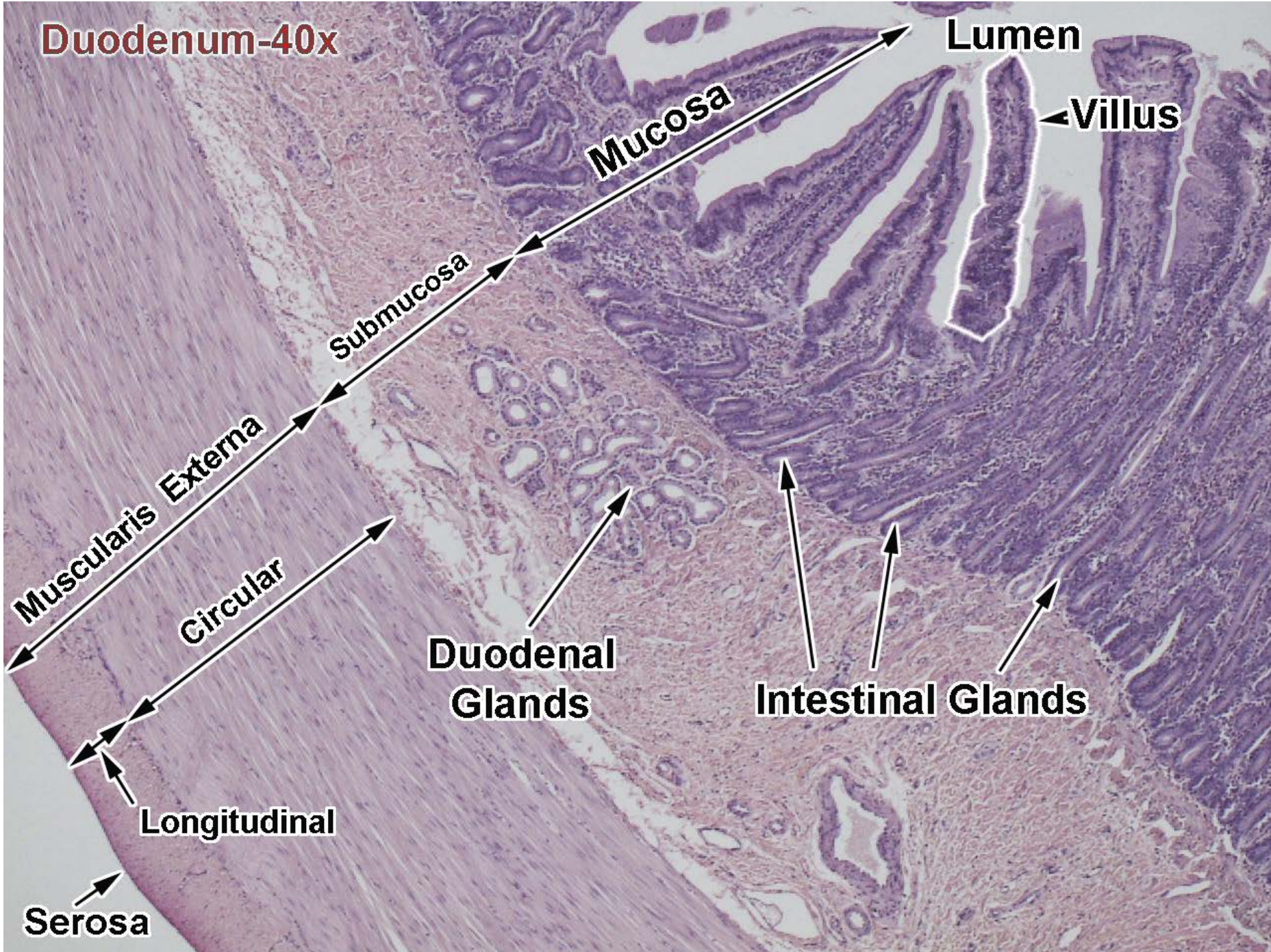
Chief Cells

**Stomach
Slide**

**Olexik
Website**



Duodenum-40x



**Small
Intestine
Slide**

**Olexik
Website**

Duodenum-200x

Submucosa

**Circular
Muscularis
Externa**

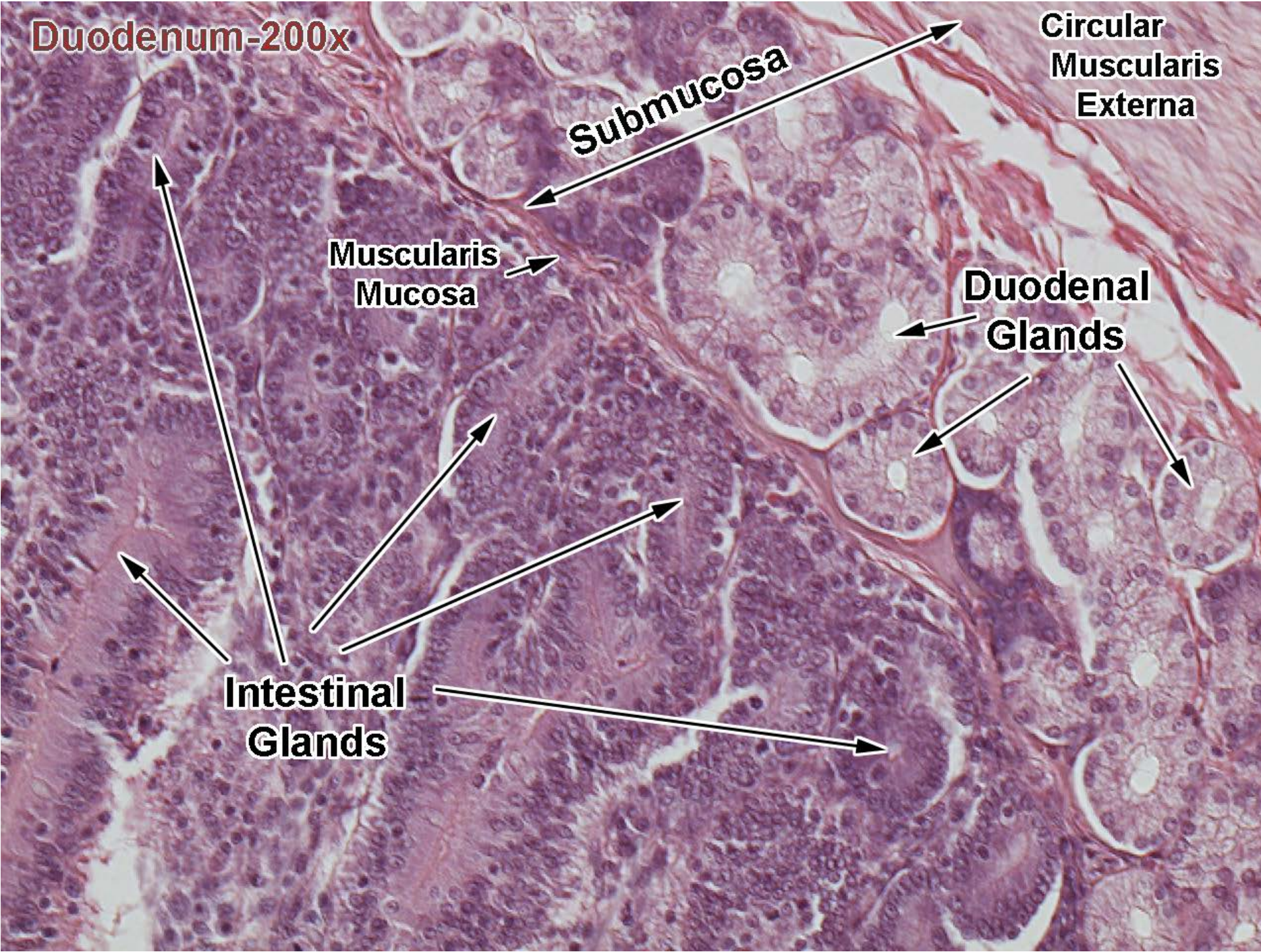**Muscularis
Mucosa**

**Duodenal
Glands**

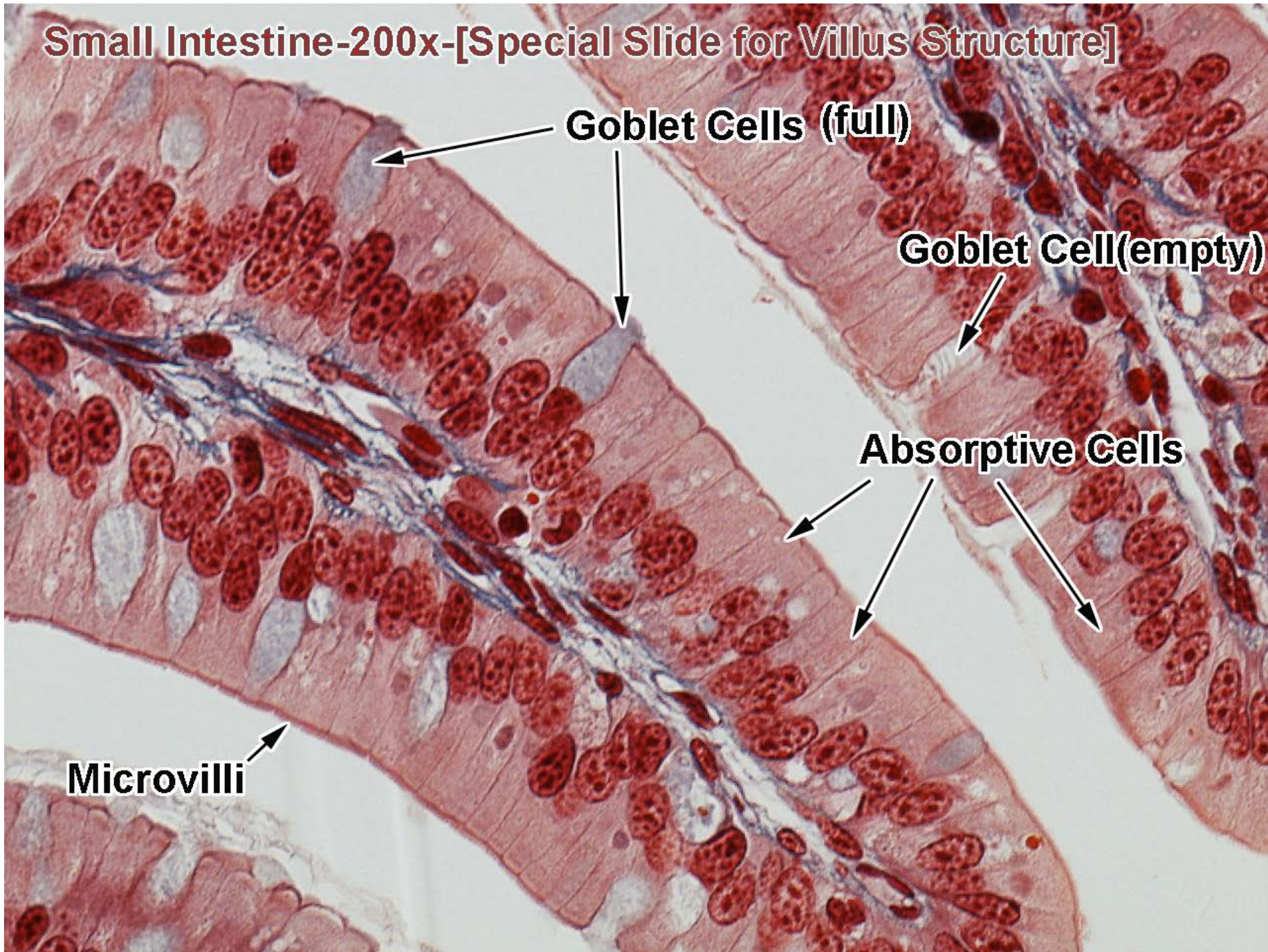
**Intestinal
Glands**

**Small
Intestine
Slide**

**Olexik
Website**



Small Intestine-200x-[Special Slide for Villus Structure]



Goblet Cells (full)

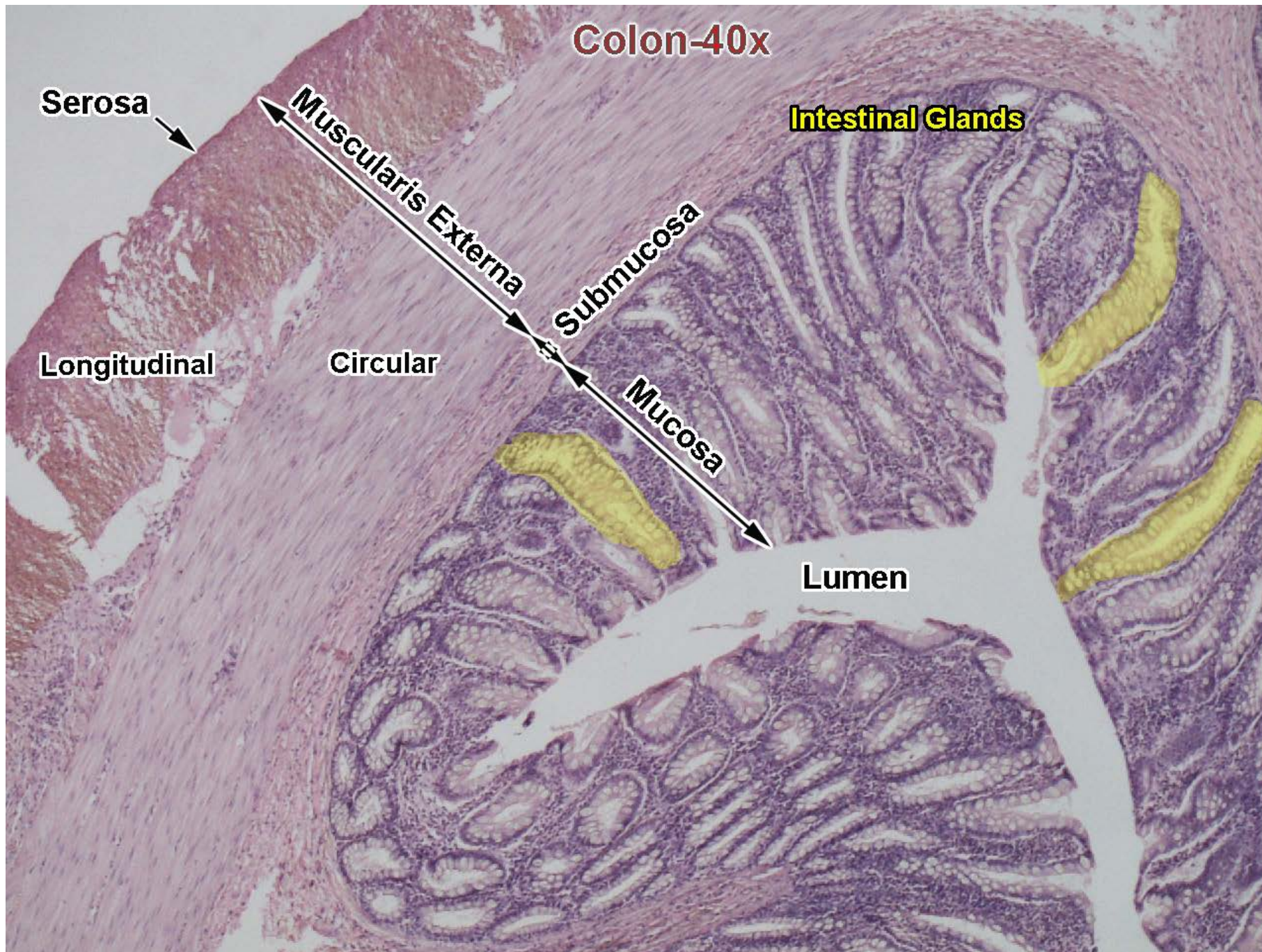
Goblet Cell(empty)

Absorptive Cells

Microvilli

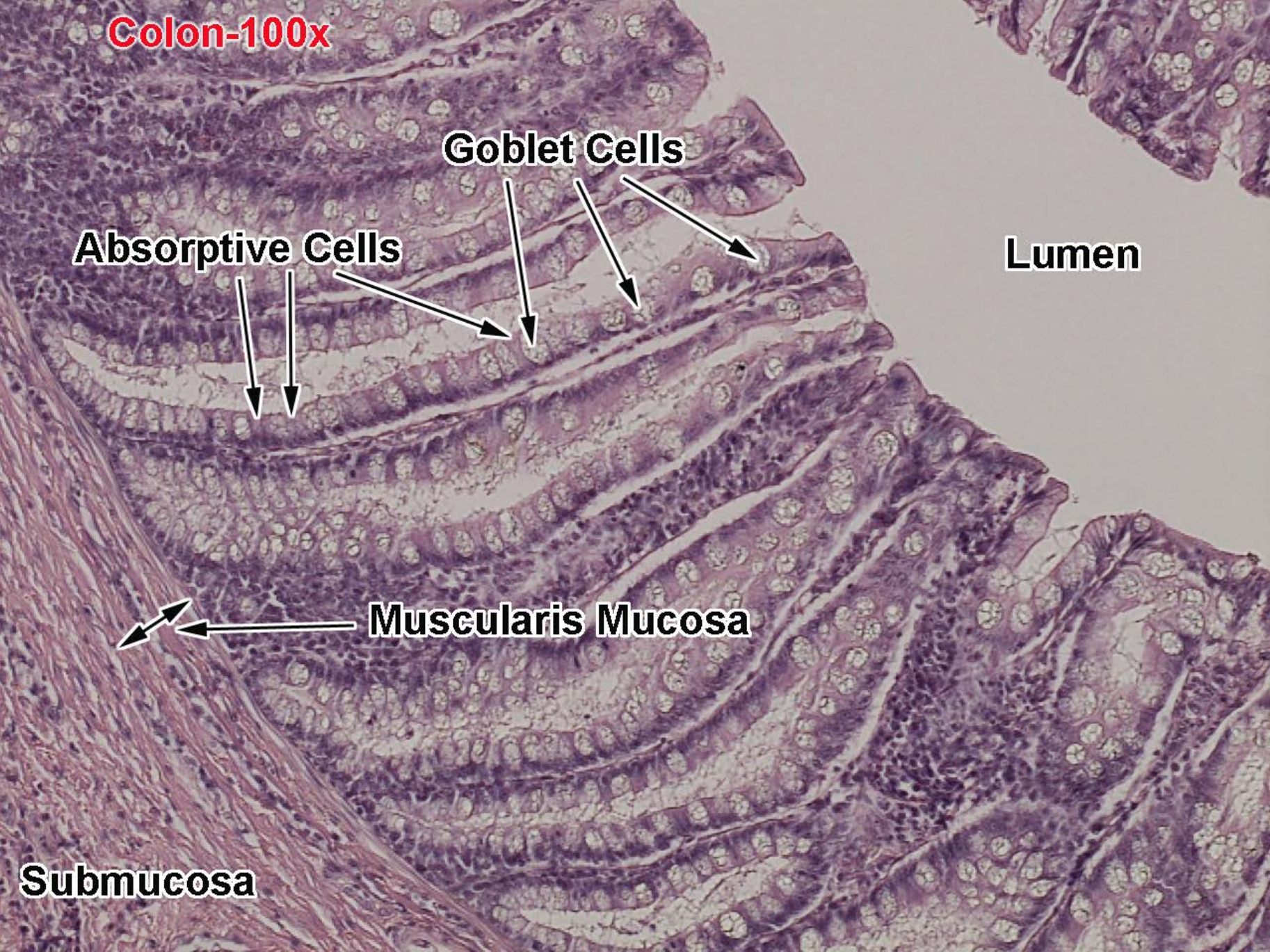
Small Intestine Slide

Olexik Website



Large
Intestine
Slide

Olexik
Website



Colon-100x

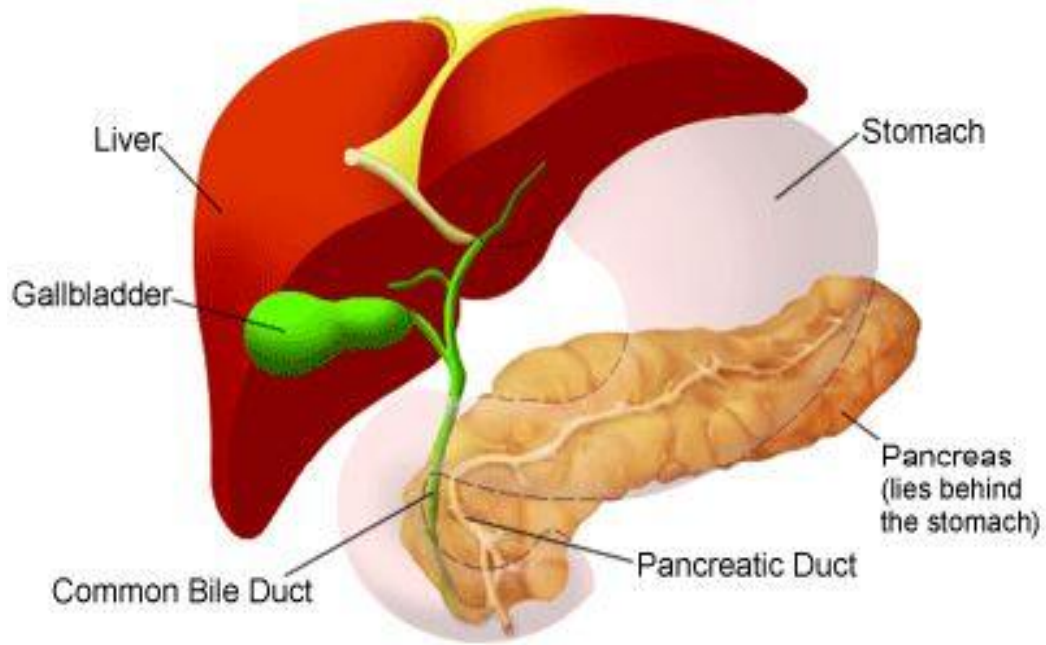
Goblet Cells

Absorptive Cells

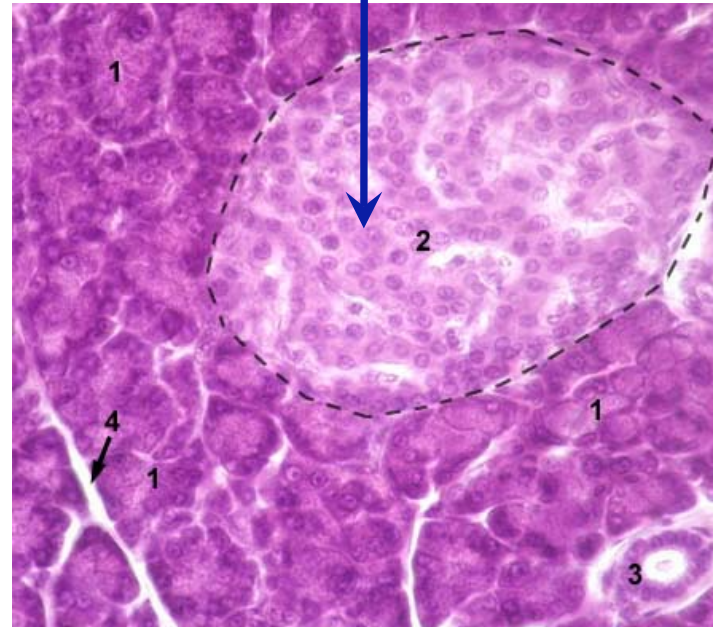
Lumen

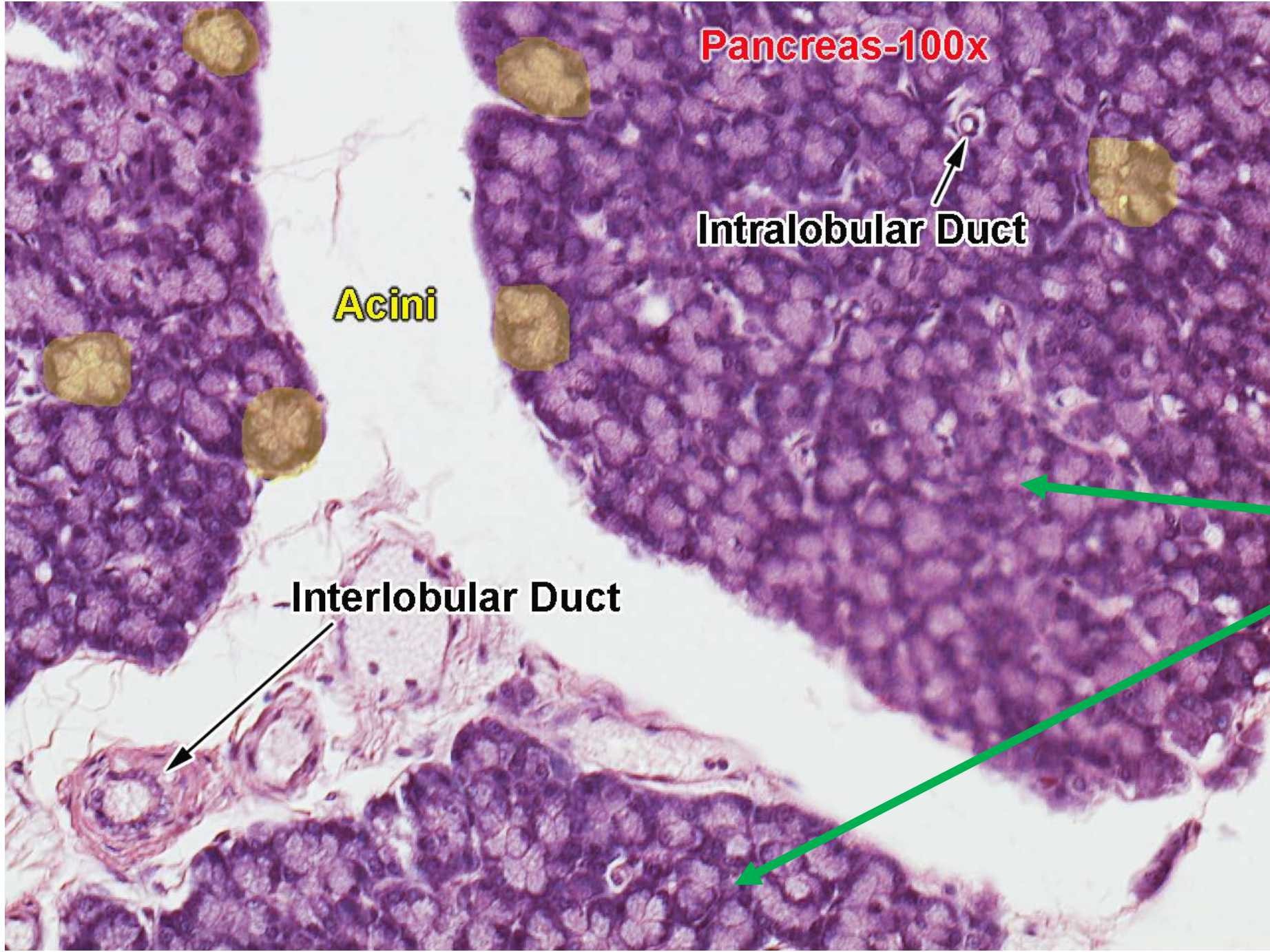
Muscularis Mucosa

Submucosa



Islet of Langerhans





Pancreas-100x

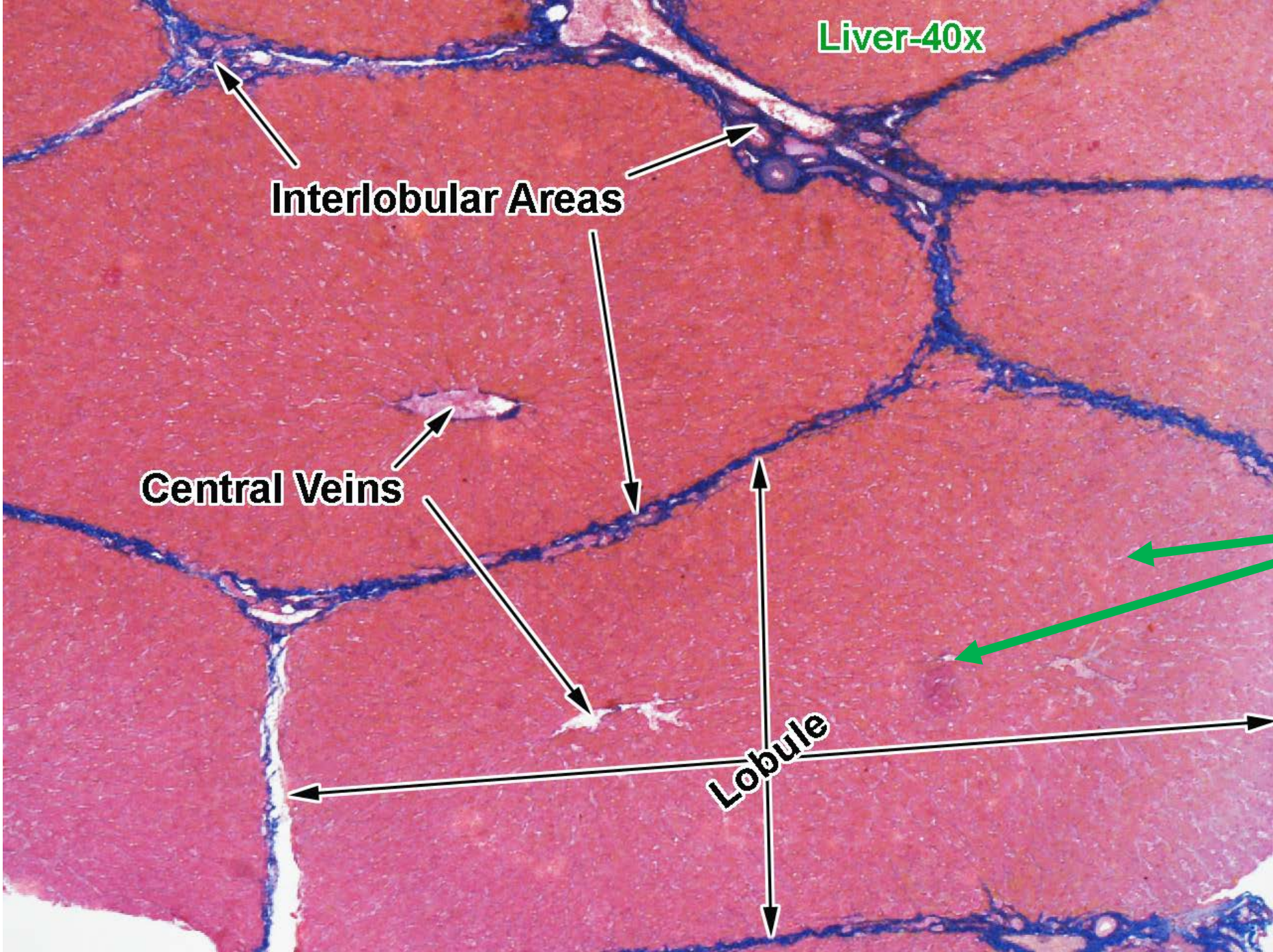
Intralobular Duct

Acini

Interlobular Duct

Lobules

(Full structures
containing acini and
intralobular ducts in
this view.)



Liver-40x

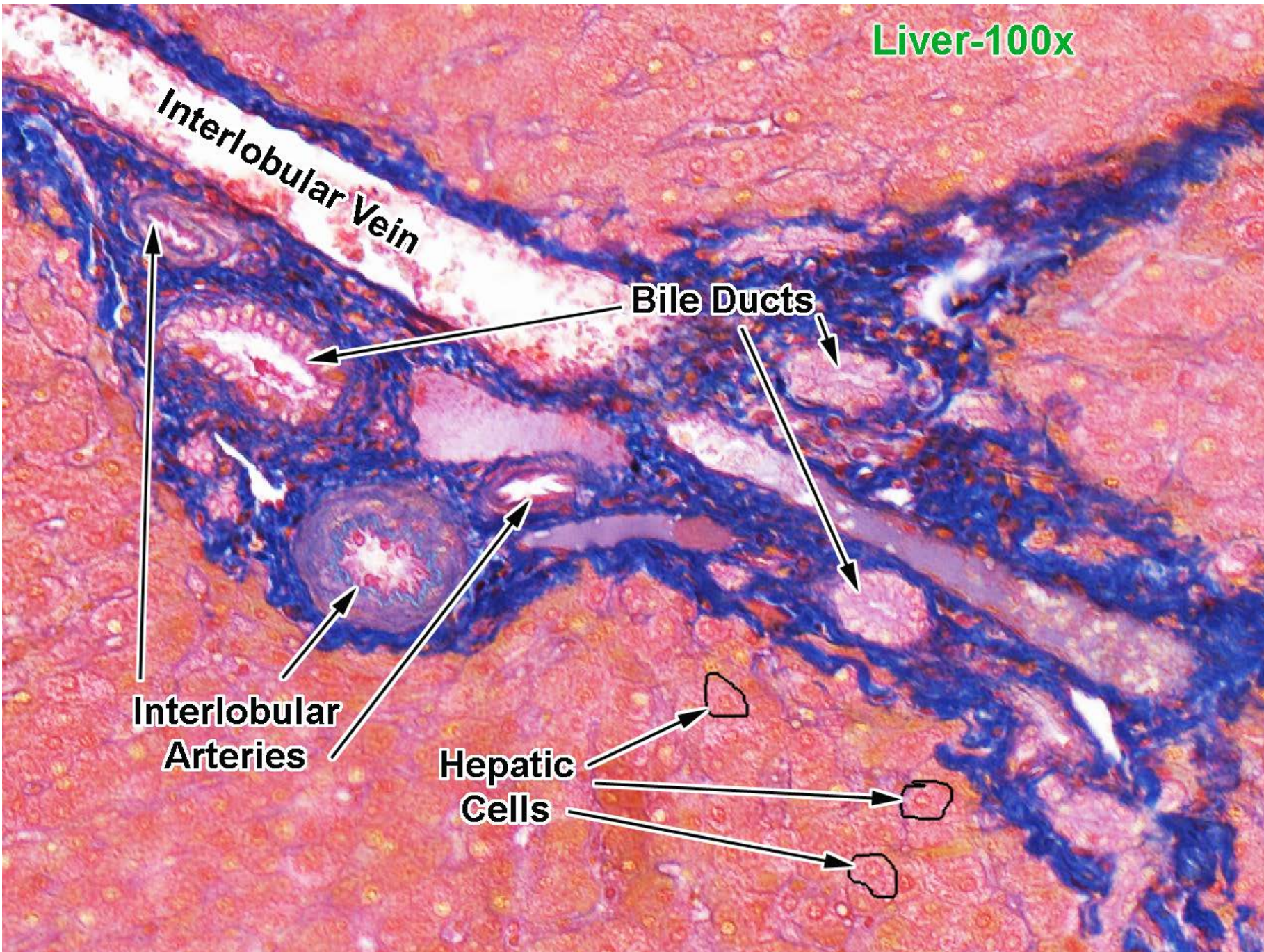
Interlobular Areas

Central Veins

Lobule

Sinusoids

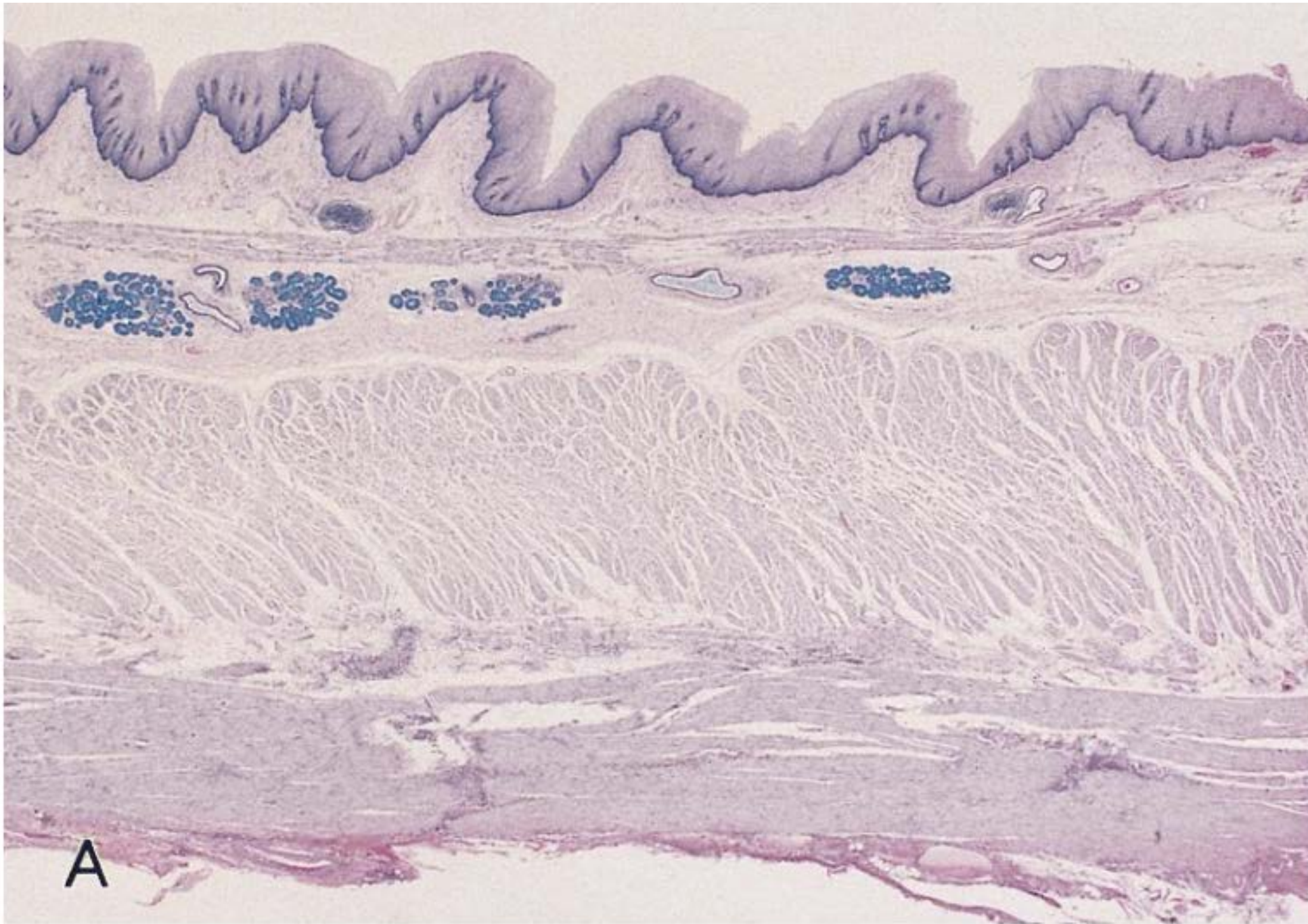
(Smaller open spaces in lobule.)



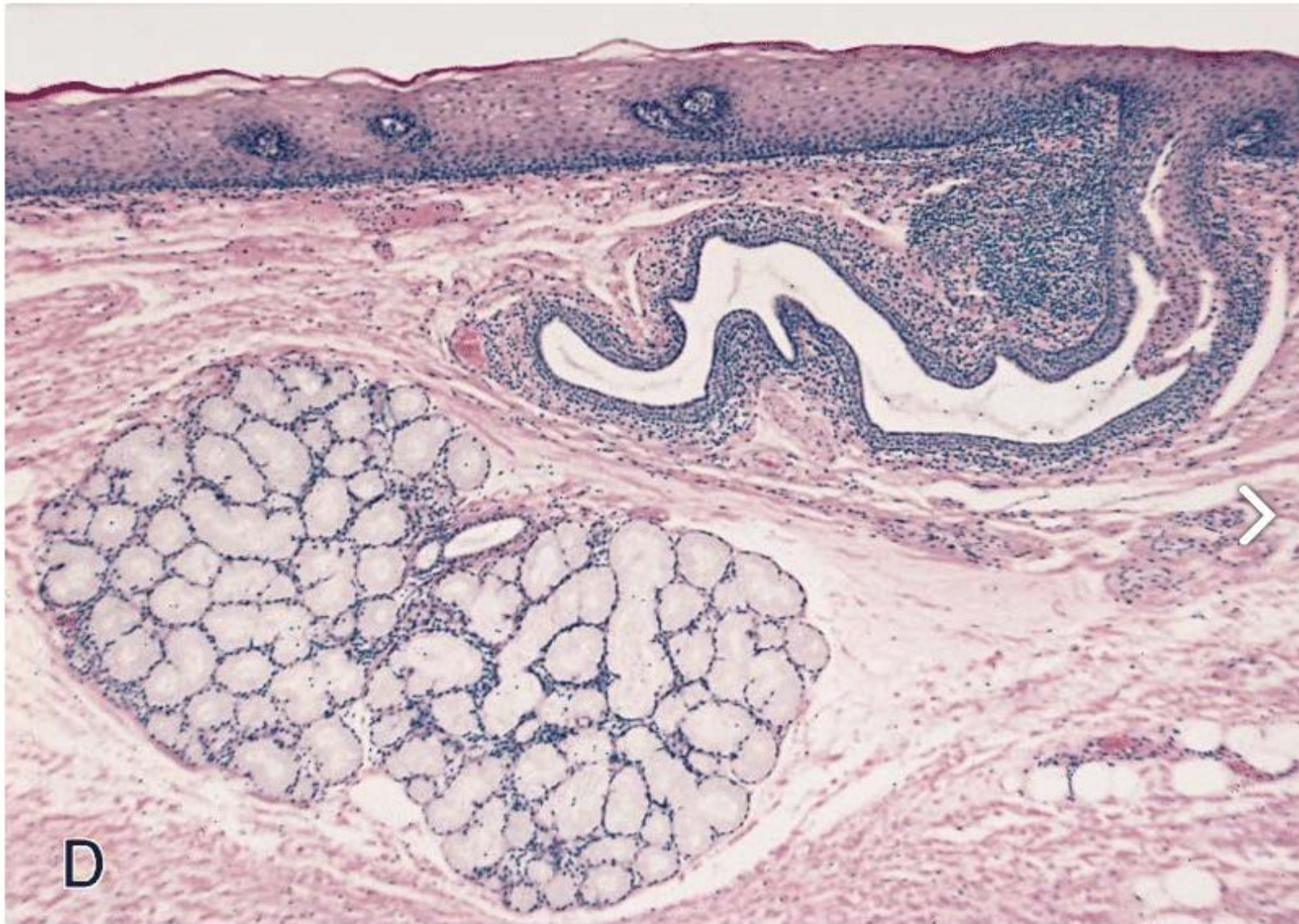
Use the following pictures to help
you practice finding the terms
from the lab term handout on
unlabeled images.

- Remember, you won't learn them if you don't take plenty of time to practice on pictures with NO labels (including no labels for what type of slide it is on histology pictures)!
- Also, be sure to mix up the order once you get comfortable with the unlabeled slides.
- Over the weekend, once you are feeling confident with the pictures here, do the histology quizzes in PAL (from the Pearson website) to get practice with new pictures that you haven't seen.

**Esophagus
Slide**

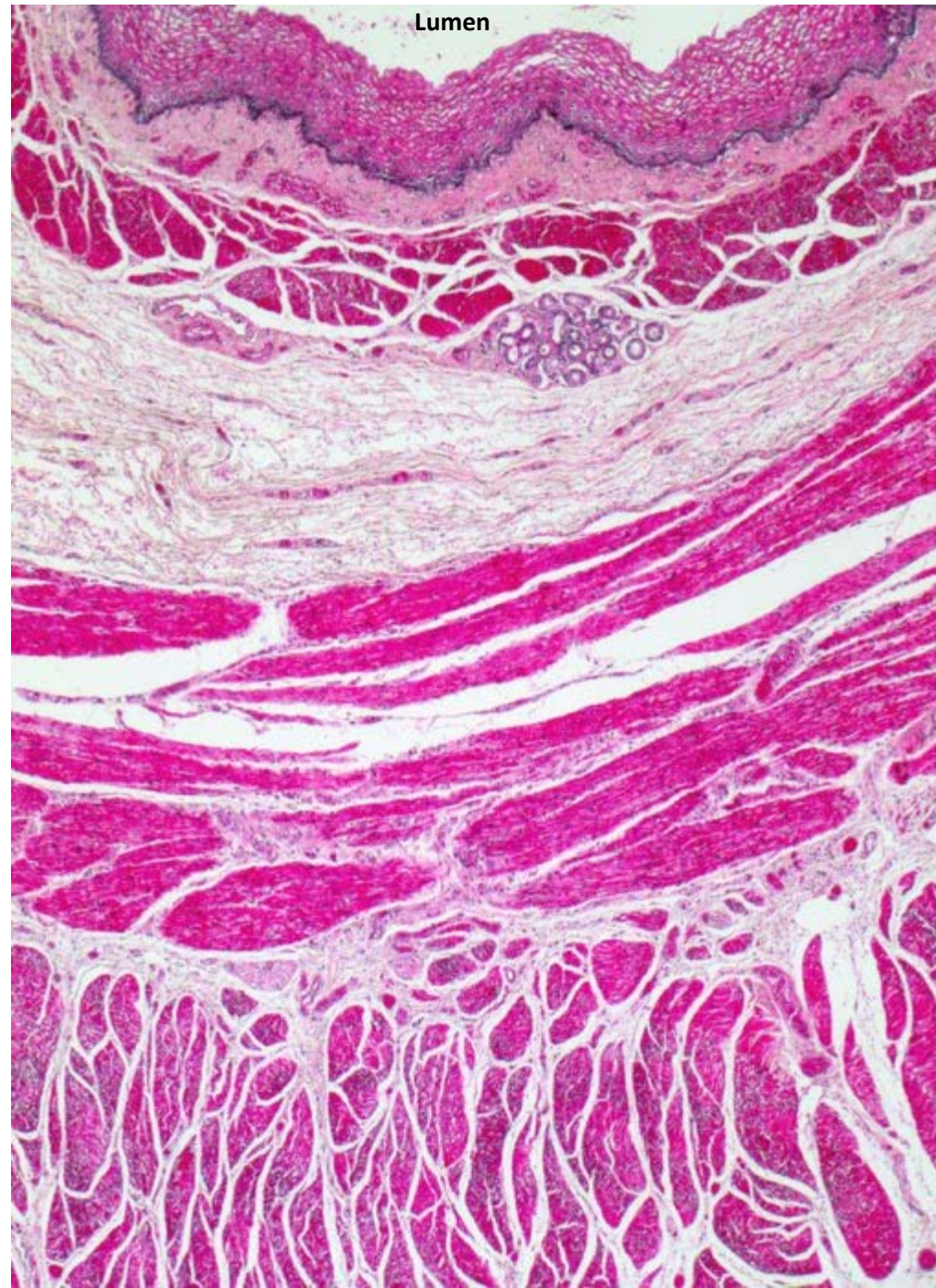


Esophagus Slide

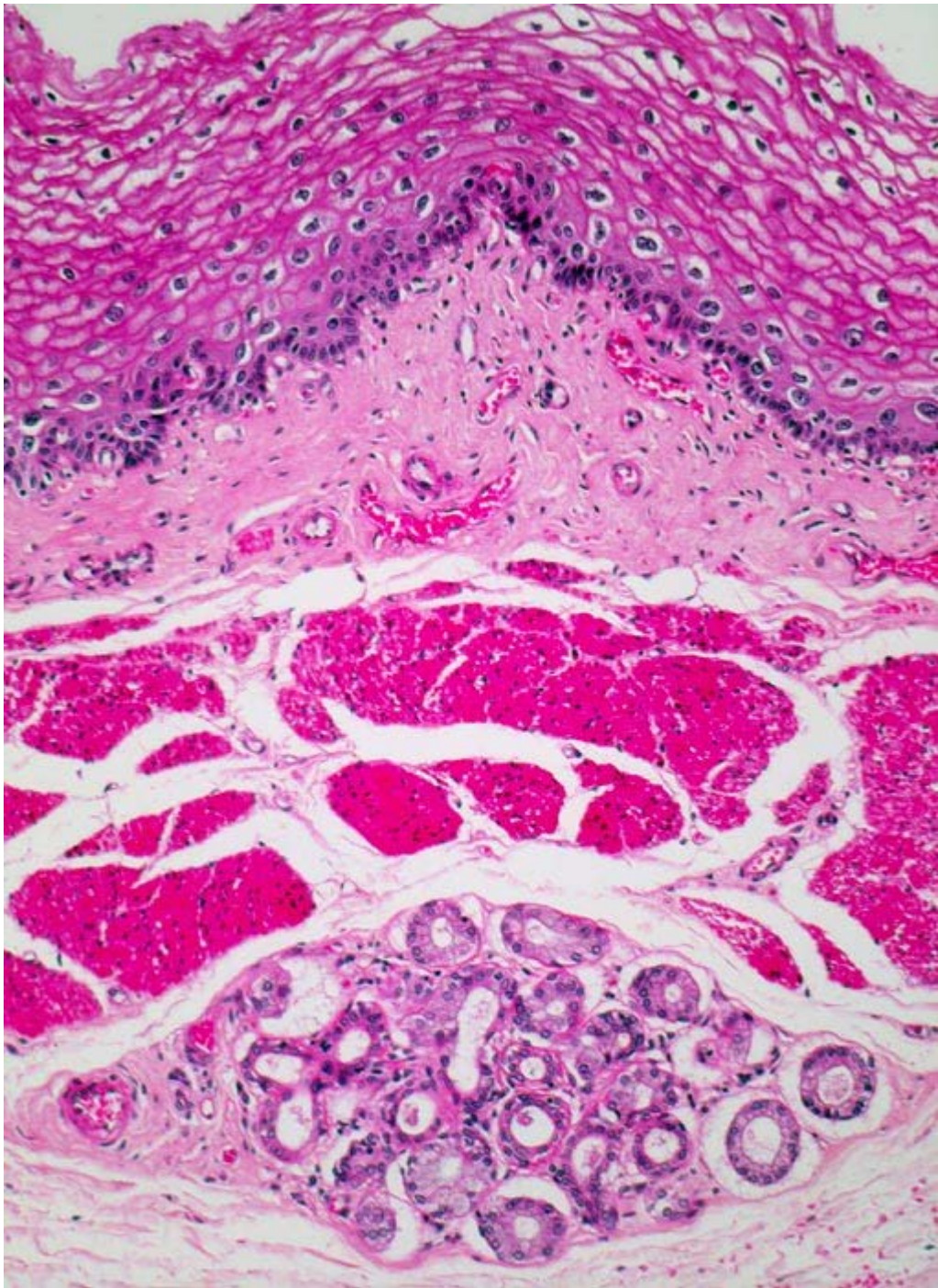


HISTOLOGIC FEATURES OF THE ESOPHAGUS

D: Section of esophageal mucosa shows a duct originating from the submucosal glands penetrating the squamous epithelium.

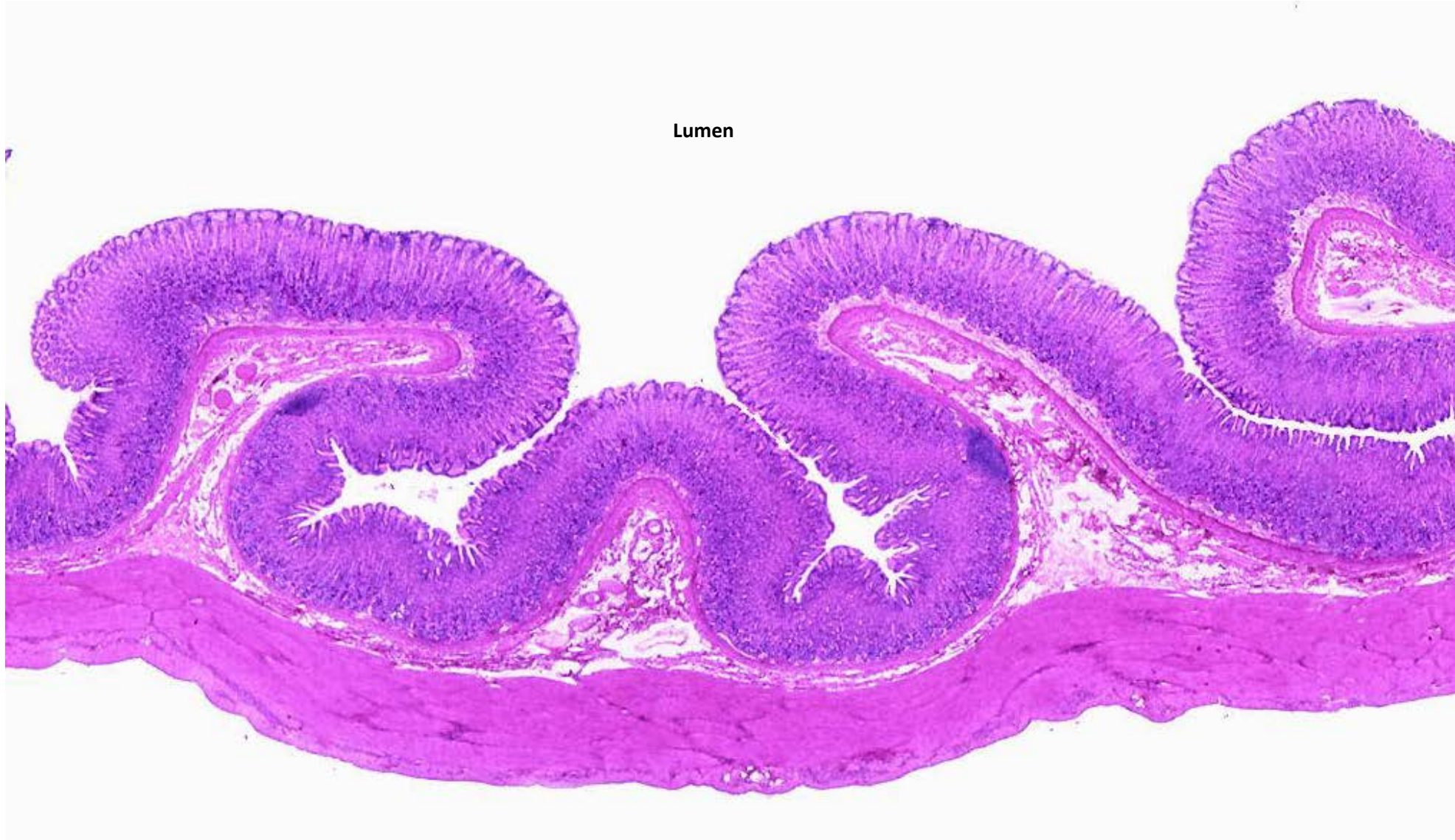

**Esophagus
Slide**



**Esophagus
Slide**

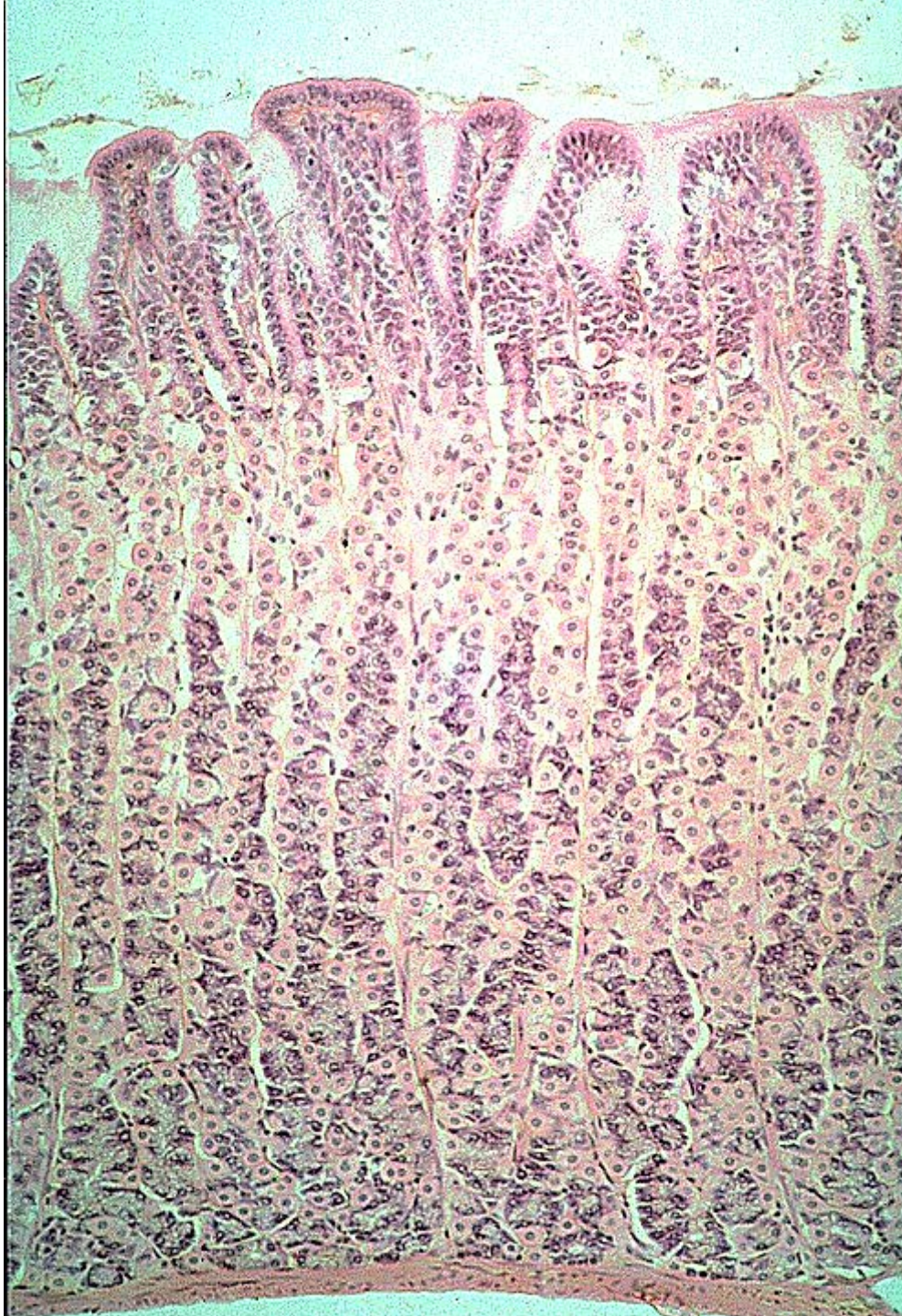
Stomach Slide

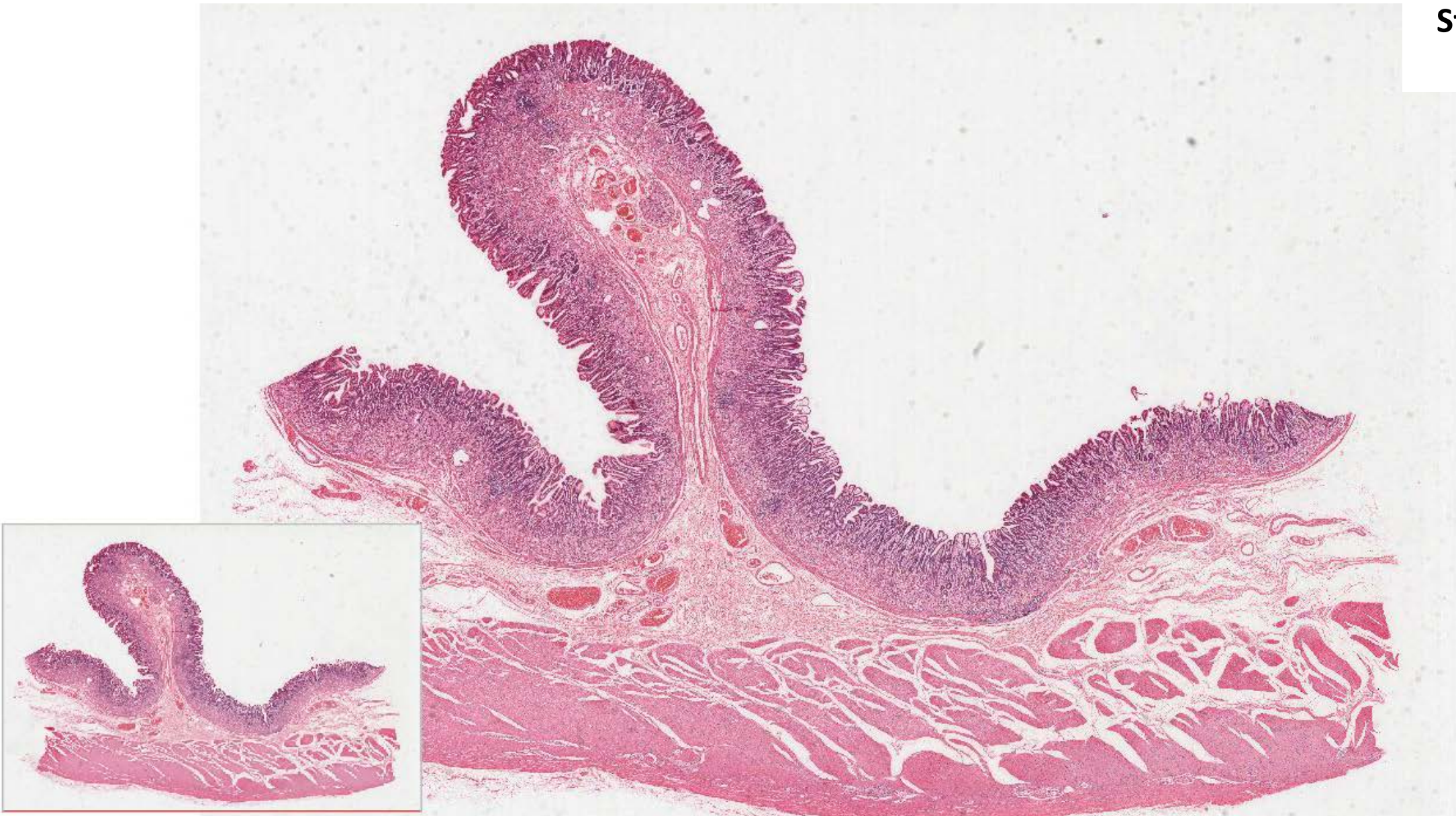

Website with interactive labels:

http://medcell.med.yale.edu/histology/gi_tract_lab/stomach.php

**Stomach Slide
(Mucosal Layer)**

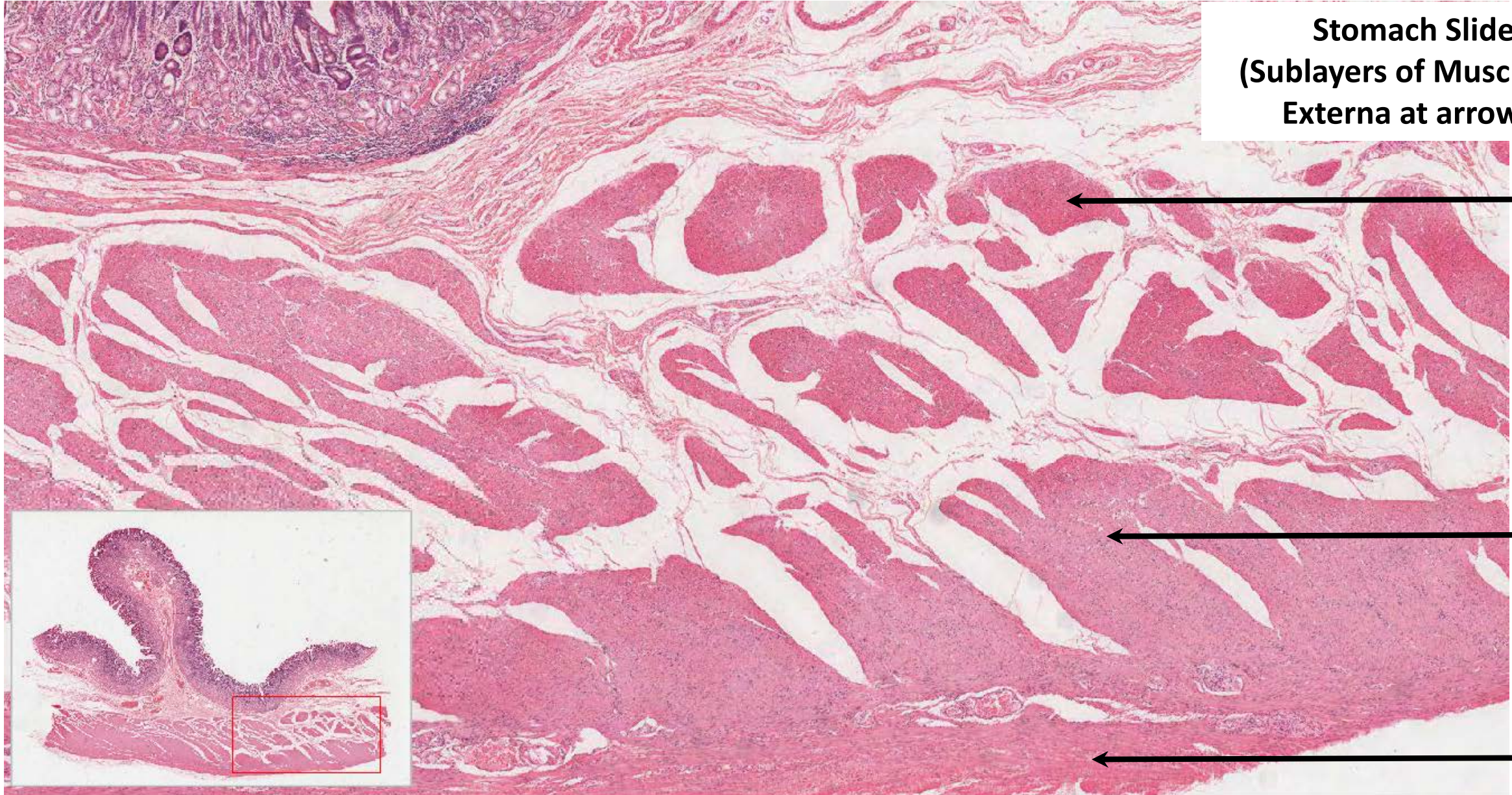




Stomach virtual microscope: http://aperio.duhs.duke.edu/UTasmania/G_038.svs/view.apml?

**Make sure Adobe Flash Player is enabled for this website.

**Stomach Slide
(Sublayers of Muscularis
Externa at arrows)**



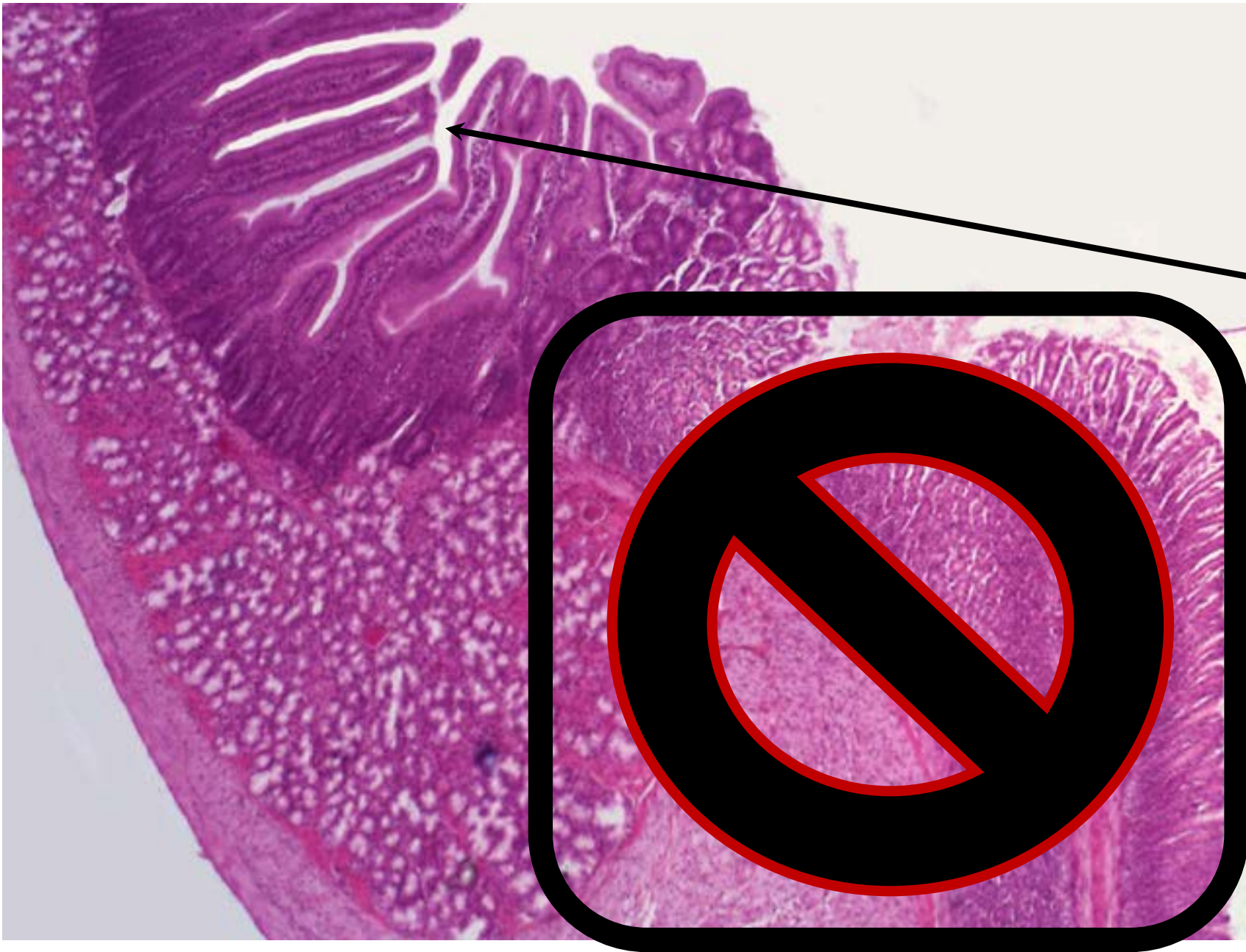Stomach virtual microscope: http://aperio.duhs.duke.edu/UTasmania/G_038.svs/view.apml?

**Make sure Adobe Flash Player is enabled for this website.

Stomach virtual microscope: <http://aperio.duhs.duke.edu/UCincinnati/38548.svs/view.apml?>

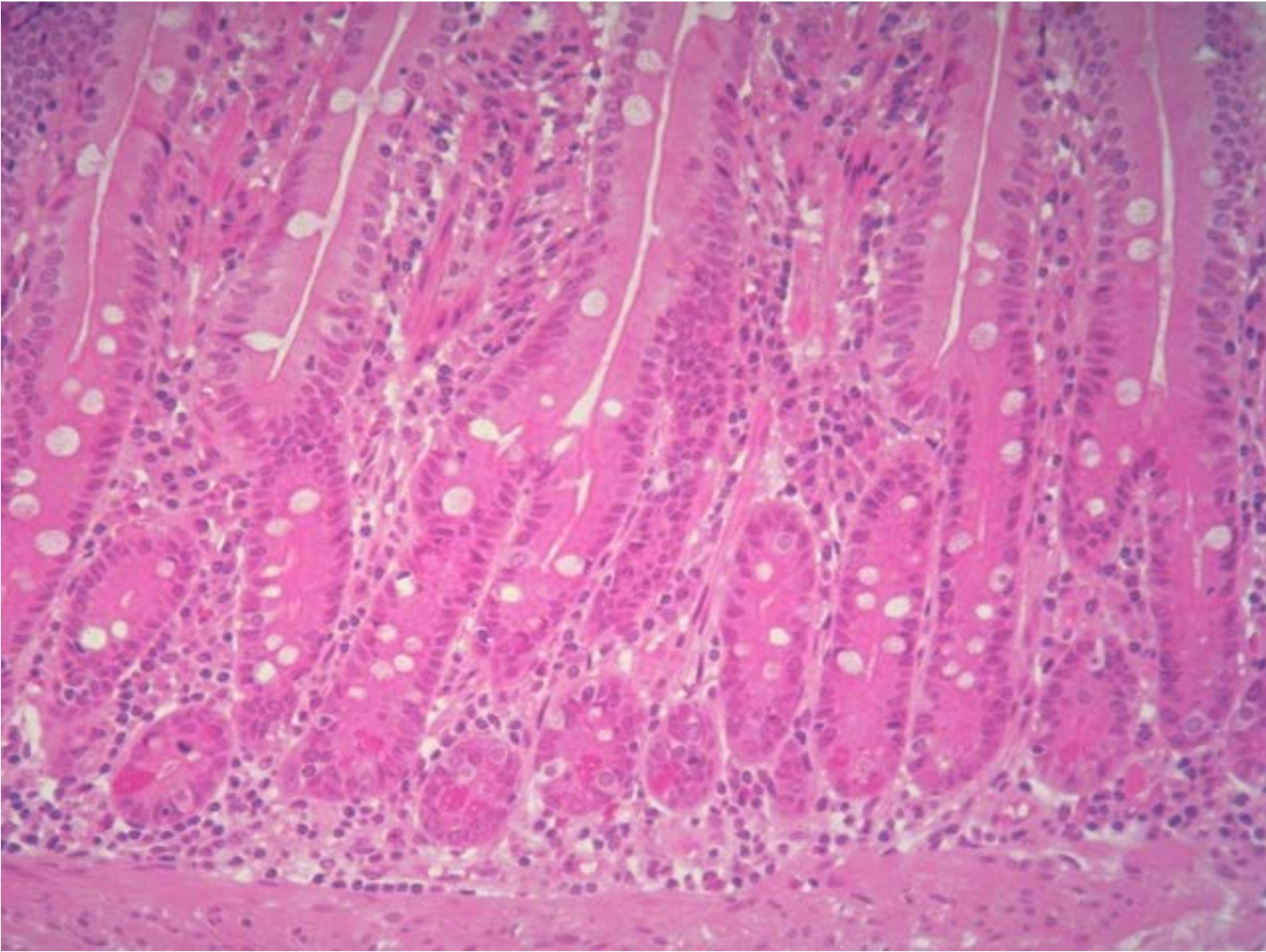
**Make sure Adobe Flash Player is enabled for this website.

**Small
Intestine
Slide**

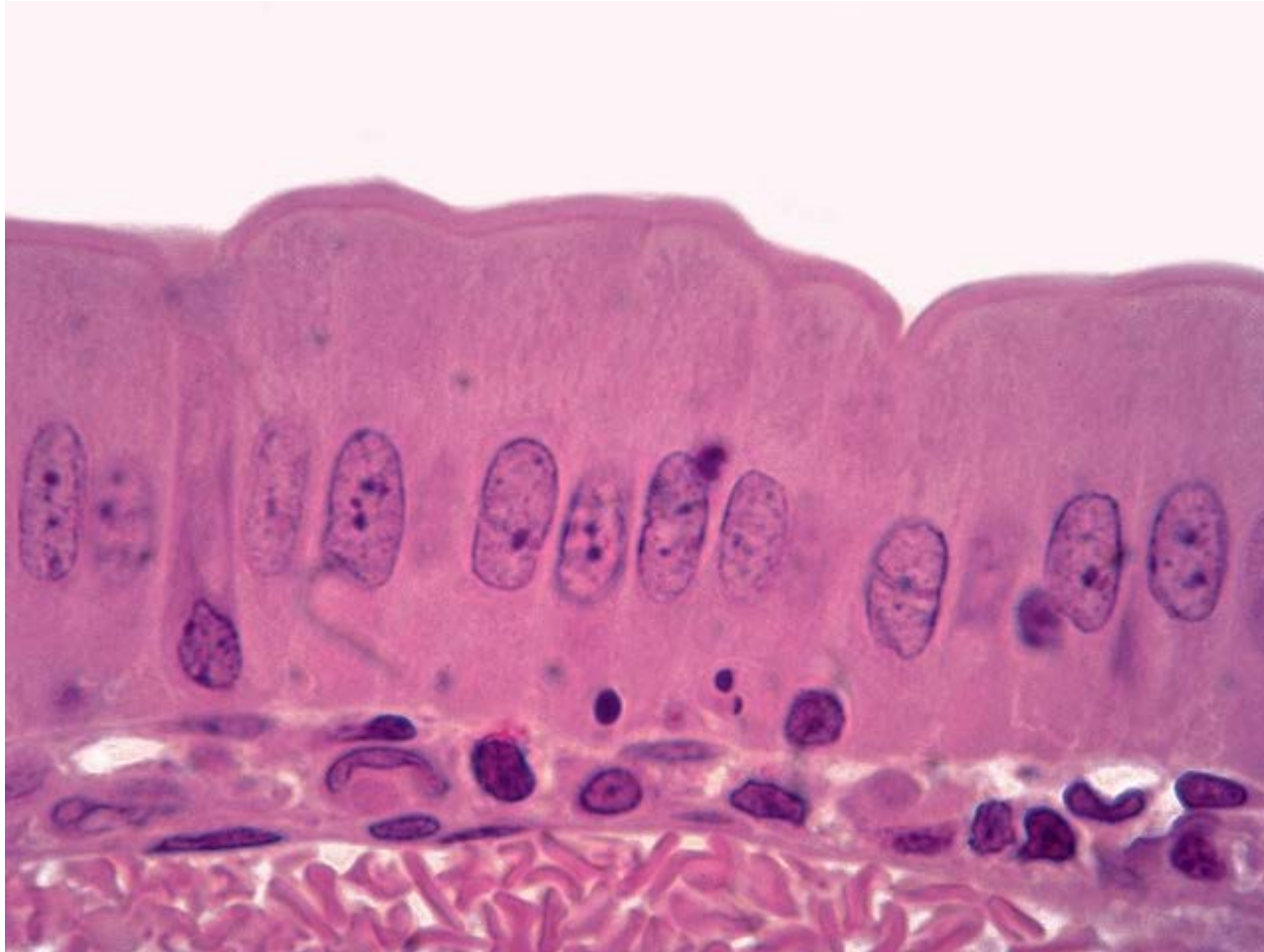


**Focus up here...not in the
area in the box.**

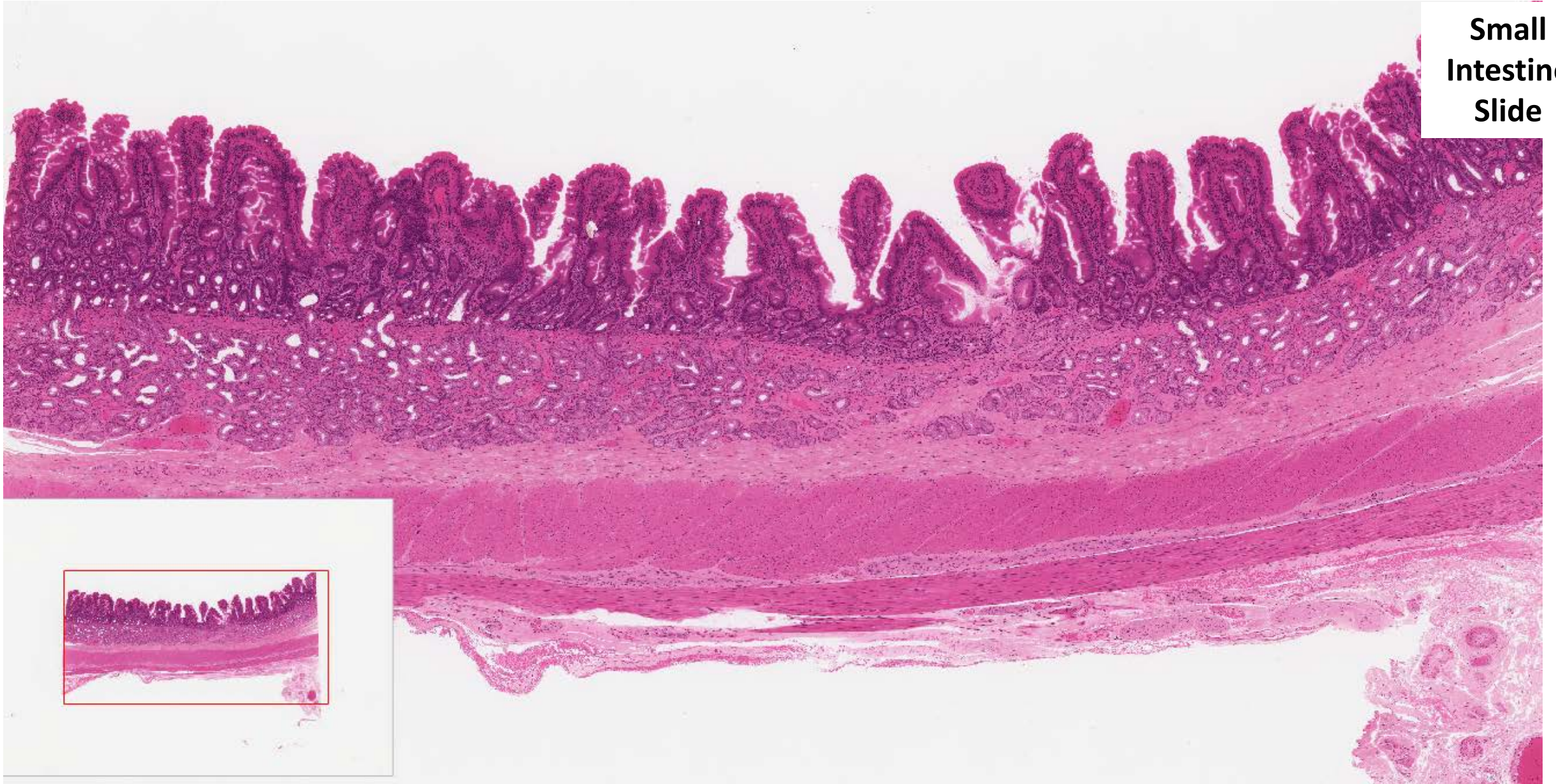
**Small
Intestine
Slide**



Small Intestine Slide (Epithelium)



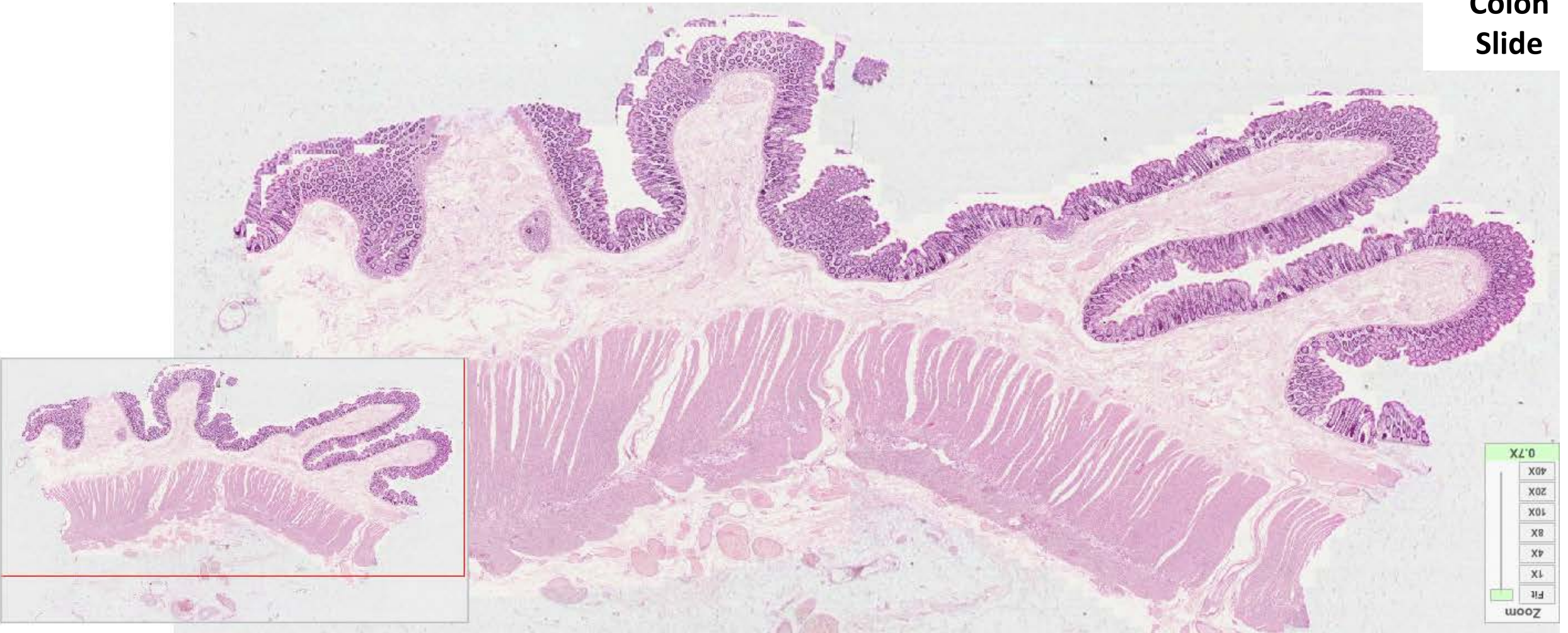
Small
Intestine
Slide



Duodenum virtual microscope: http://aperio.duhs.duke.edu/UMiss/UMiss_092_40x.svs/view.apml?

**Make sure Adobe Flash Player is enabled for this website.

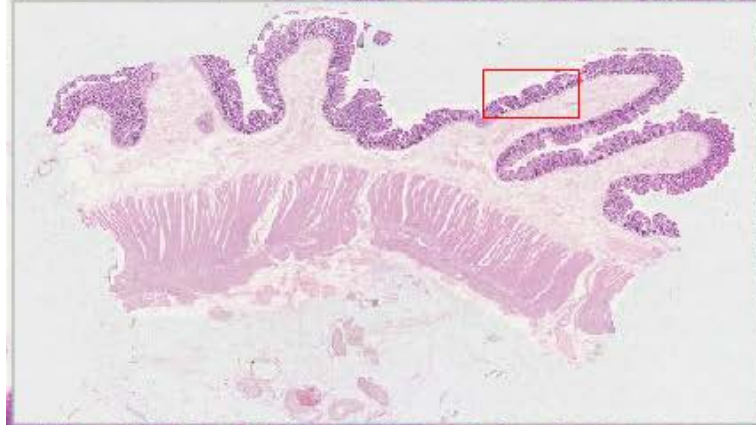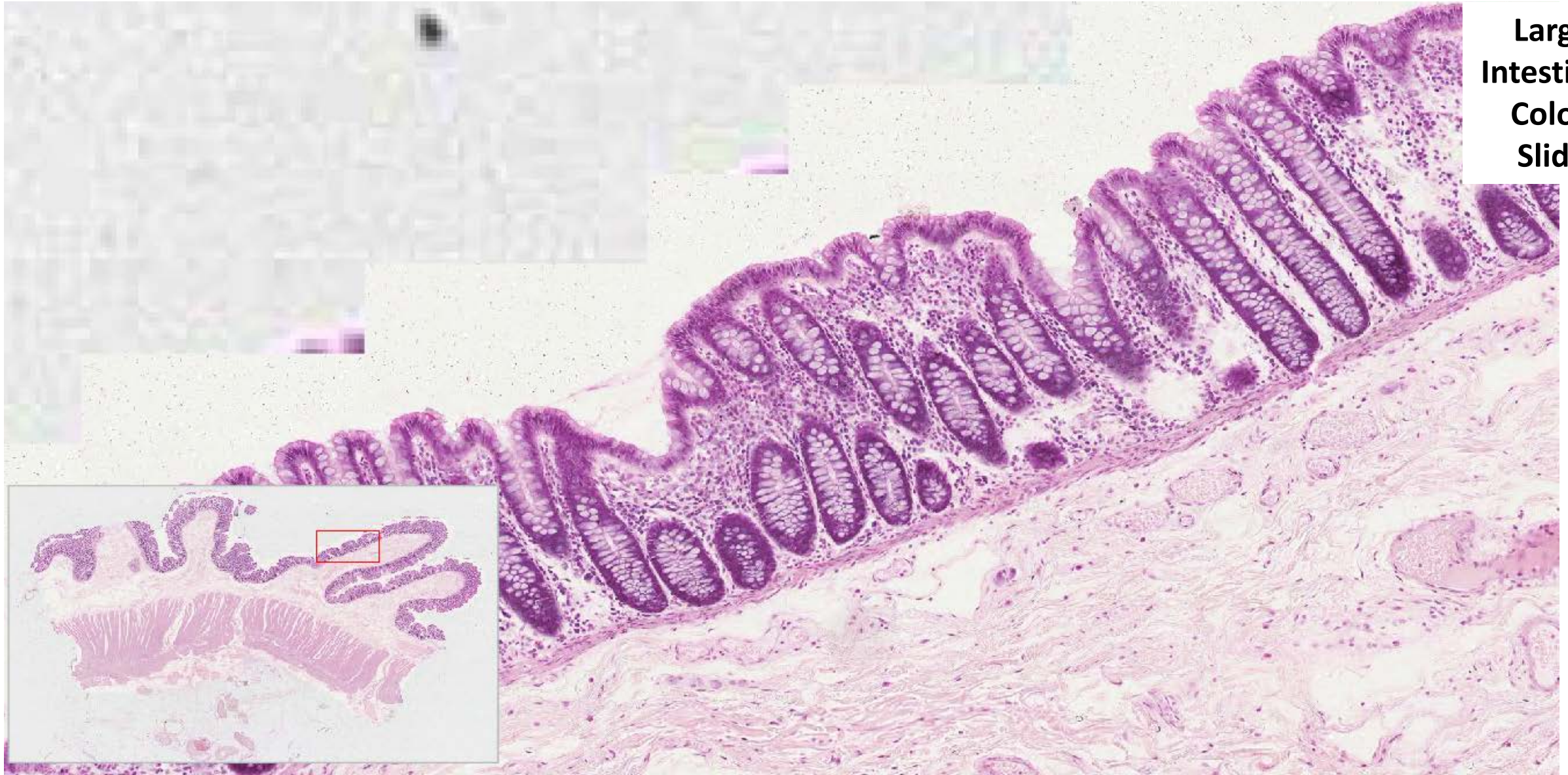
Large
Intestine/
Colon
Slide



Colon virtual microscope: [http://aperio.duhs.duke.edu/DukeHistology/GI Tract and Glands/0303 J adj.svs/view.apml?](http://aperio.duhs.duke.edu/DukeHistology/GI%20Tract%20and%20Glands/0303%20J%20adj.svs/view.apml?)

**Make sure Adobe Flash Player is enabled for this website.

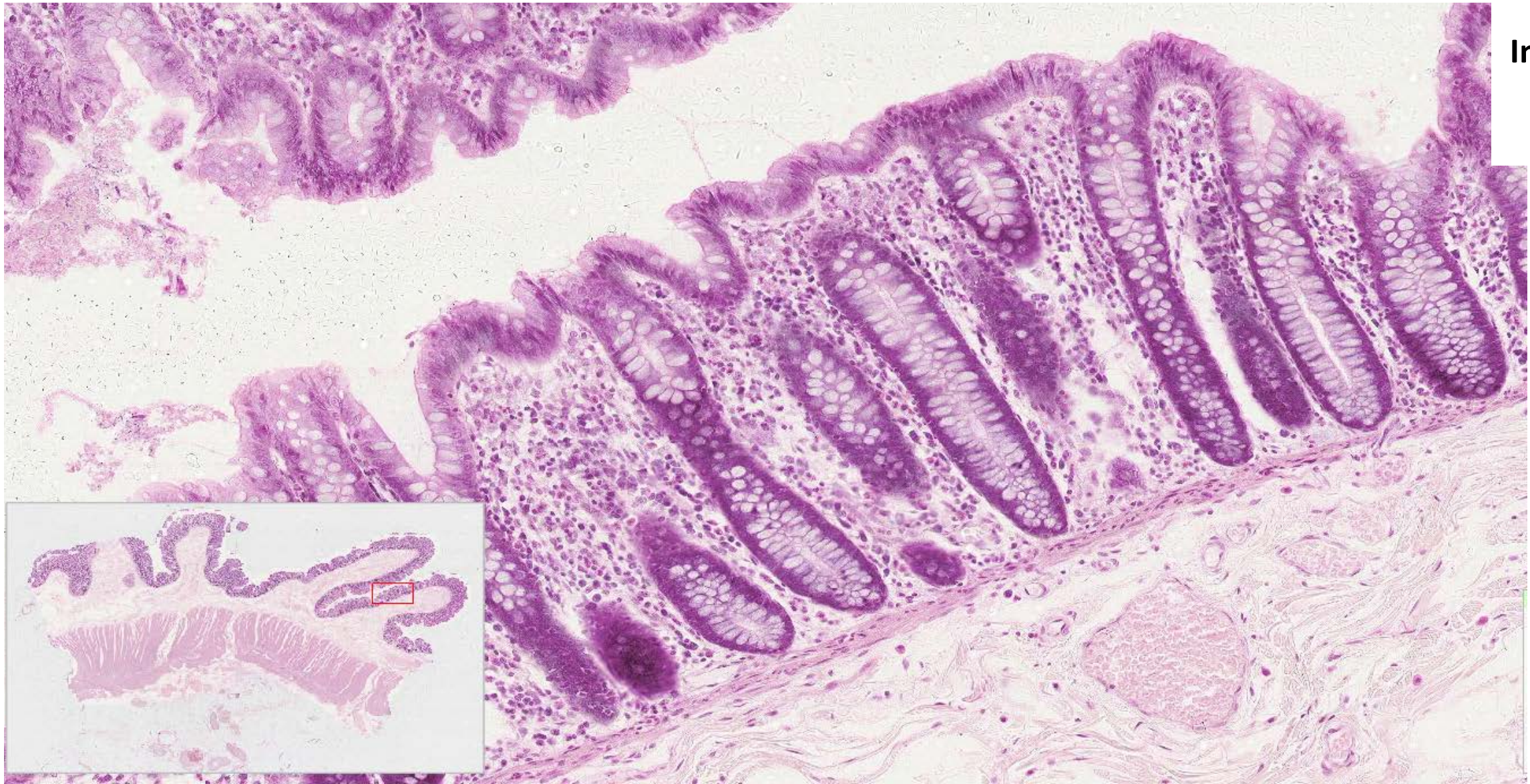
Large
Intestine/
Colon
Slide



Colon virtual microscope: [http://aperio.duhs.duke.edu/DukeHistology/GI Tract and Glands/0303 J adj.svs/view.apml?](http://aperio.duhs.duke.edu/DukeHistology/GI%20Tract%20and%20Glands/0303%20J%20adj.svs/view.apml?)

**Make sure Adobe Flash Player is enabled for this website.

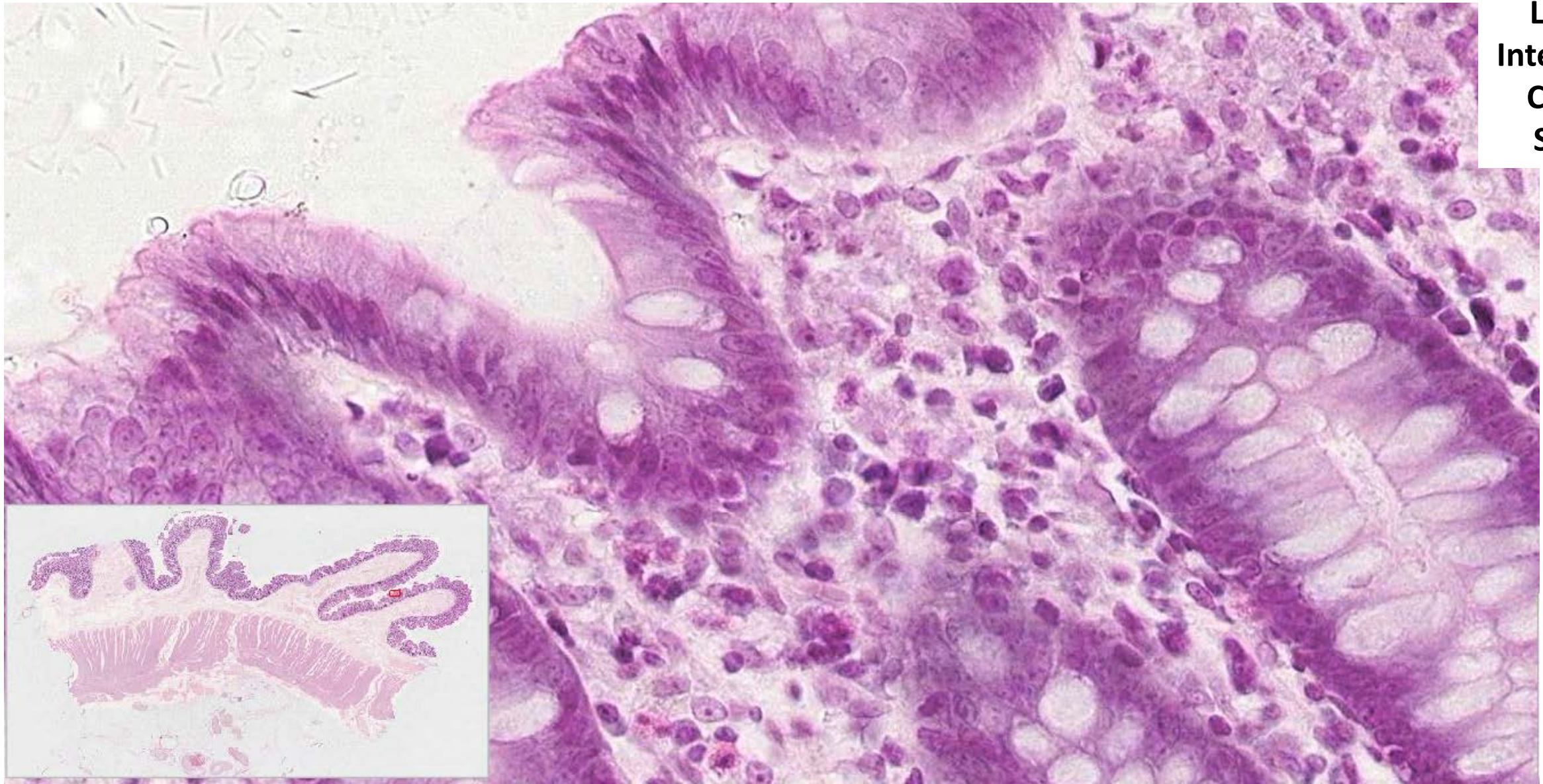
Large
Intestine/
Colon
Slide



Colon virtual microscope: [http://aperio.duhs.duke.edu/DukeHistology/GI Tract and Glands/0303 J adj.svs/view.apml?](http://aperio.duhs.duke.edu/DukeHistology/GI%20Tract%20and%20Glands/0303%20J%20adj.svs/view.apml?)

**Make sure Adobe Flash Player is enabled for this website.

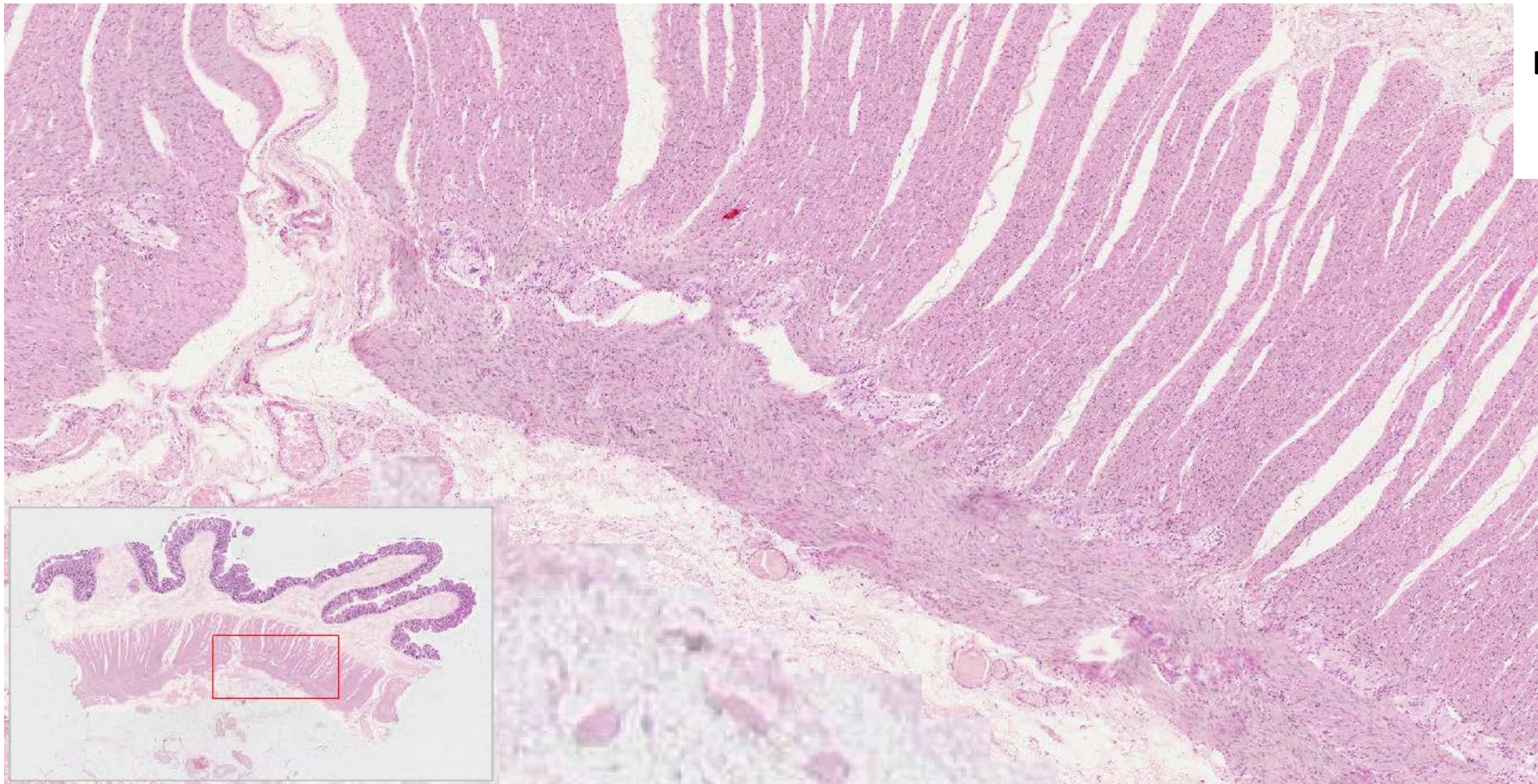
Large
Intestine/
Colon
Slide



Colon virtual microscope: [http://aperio.duhs.duke.edu/DukeHistology/GI Tract and Glands/0303 J adj.svs/view.apml?](http://aperio.duhs.duke.edu/DukeHistology/GI%20Tract%20and%20Glands/0303%20J%20adj.svs/view.apml?)

**Make sure Adobe Flash Player is enabled for this website.

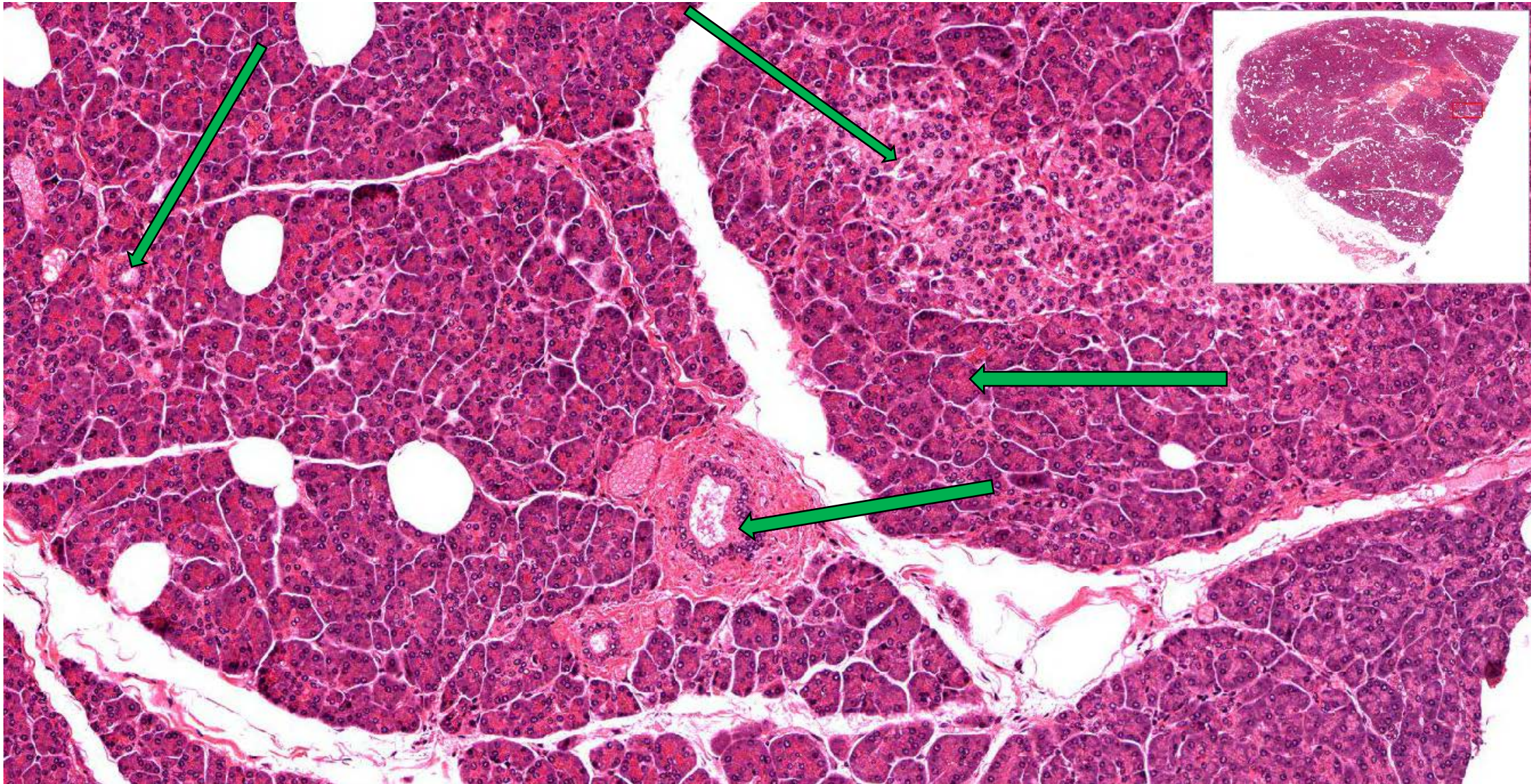
**Large
Intestine/
Colon
Slide**



Colon virtual microscope: [http://aperio.duhs.duke.edu/DukeHistology/GI Tract and Glands/0303 J adj.svs/view.apml?](http://aperio.duhs.duke.edu/DukeHistology/GI%20Tract%20and%20Glands/0303%20J%20adj.svs/view.apml?)

**Make sure Adobe Flash Player is enabled for this website.

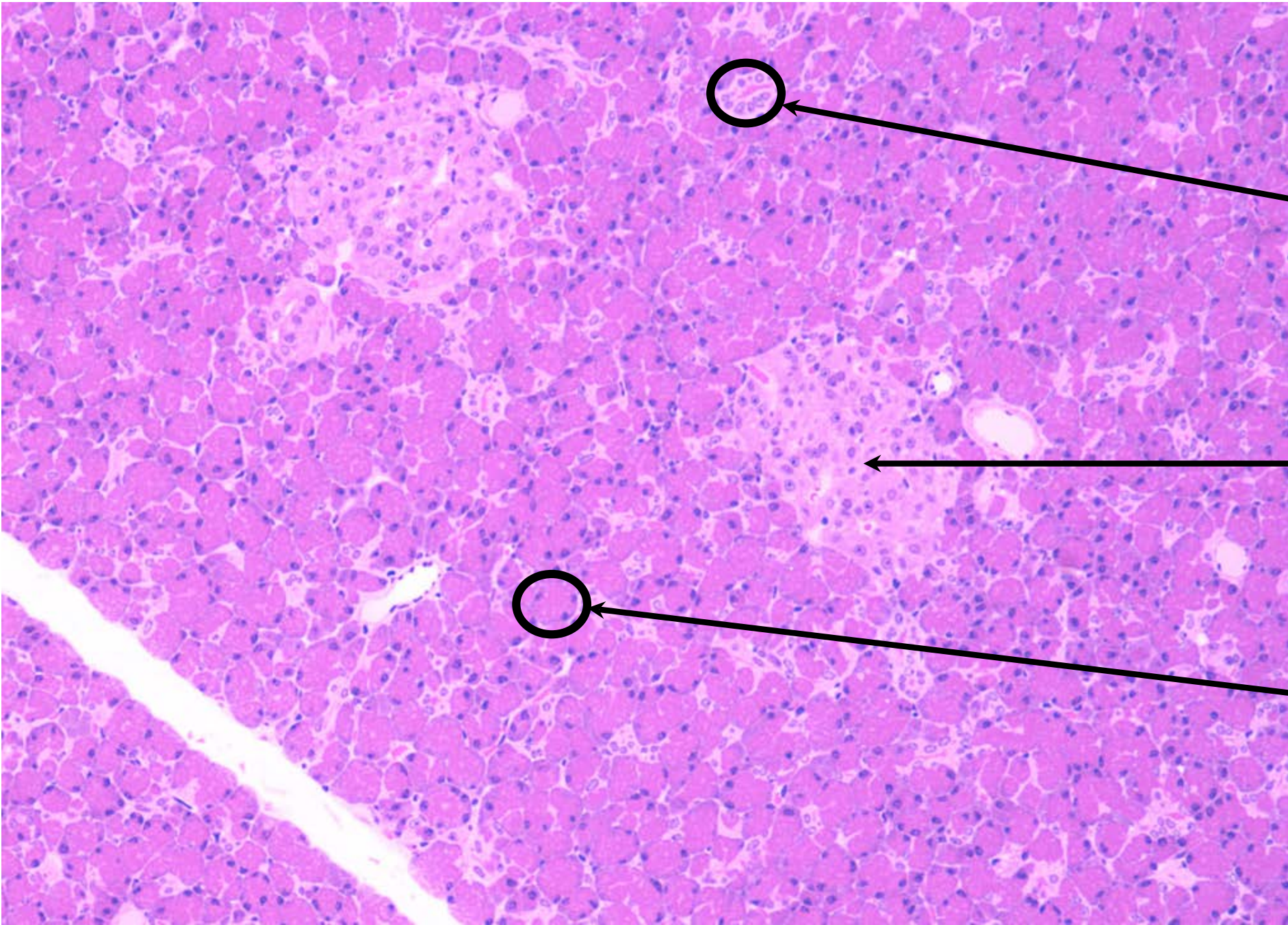
Pancreas
Slide



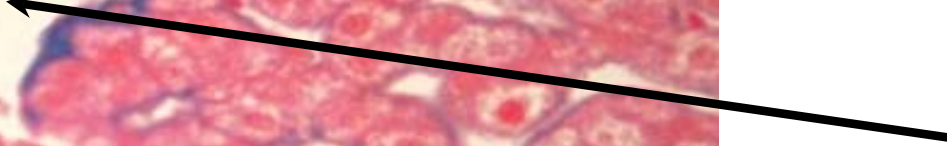
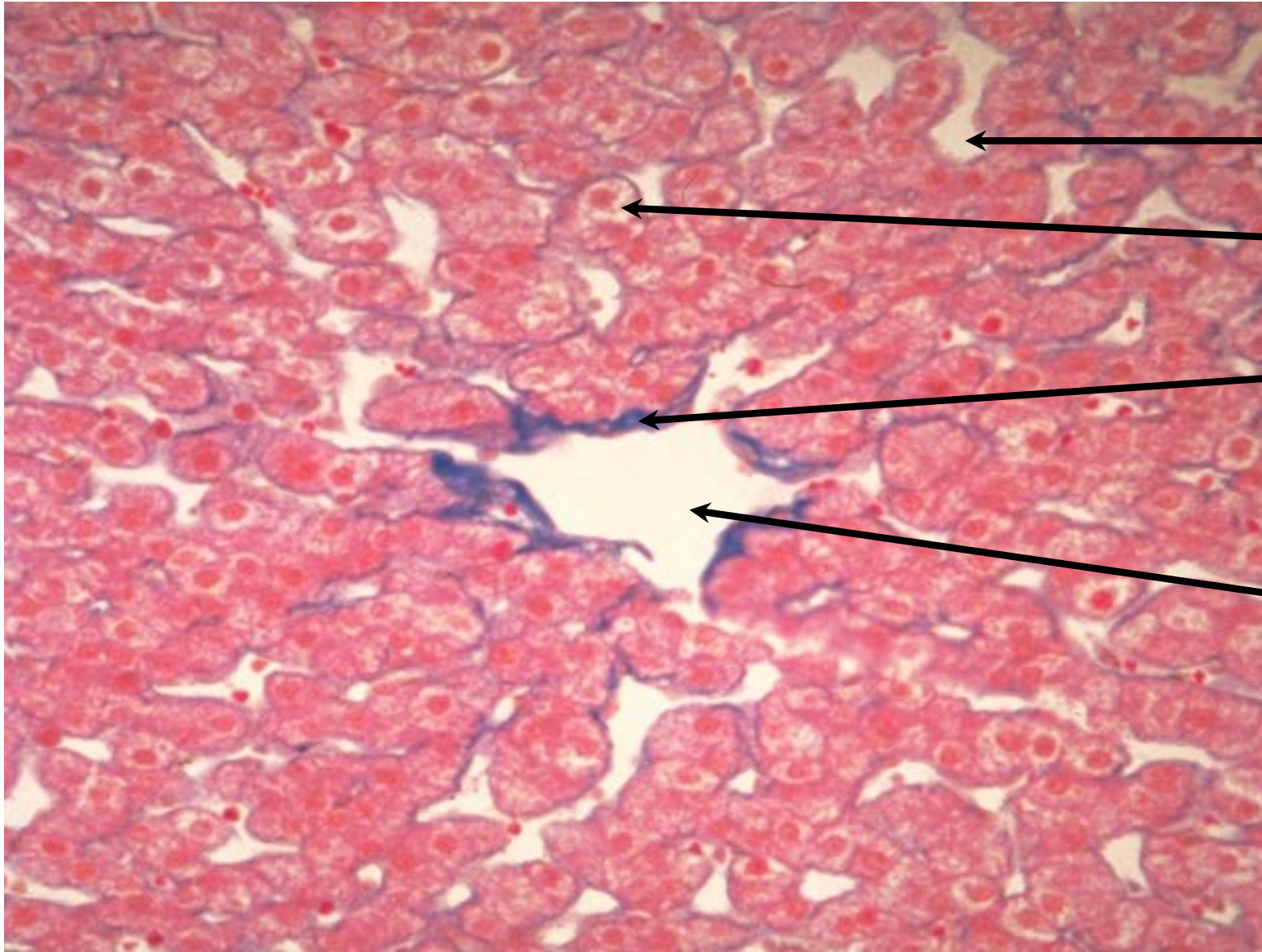
Virtual microscope: http://141.214.65.171/Histology/Digestive%20System/Liver%20and%20Pancreas/188B_HISTO_40X.svs/view.apml

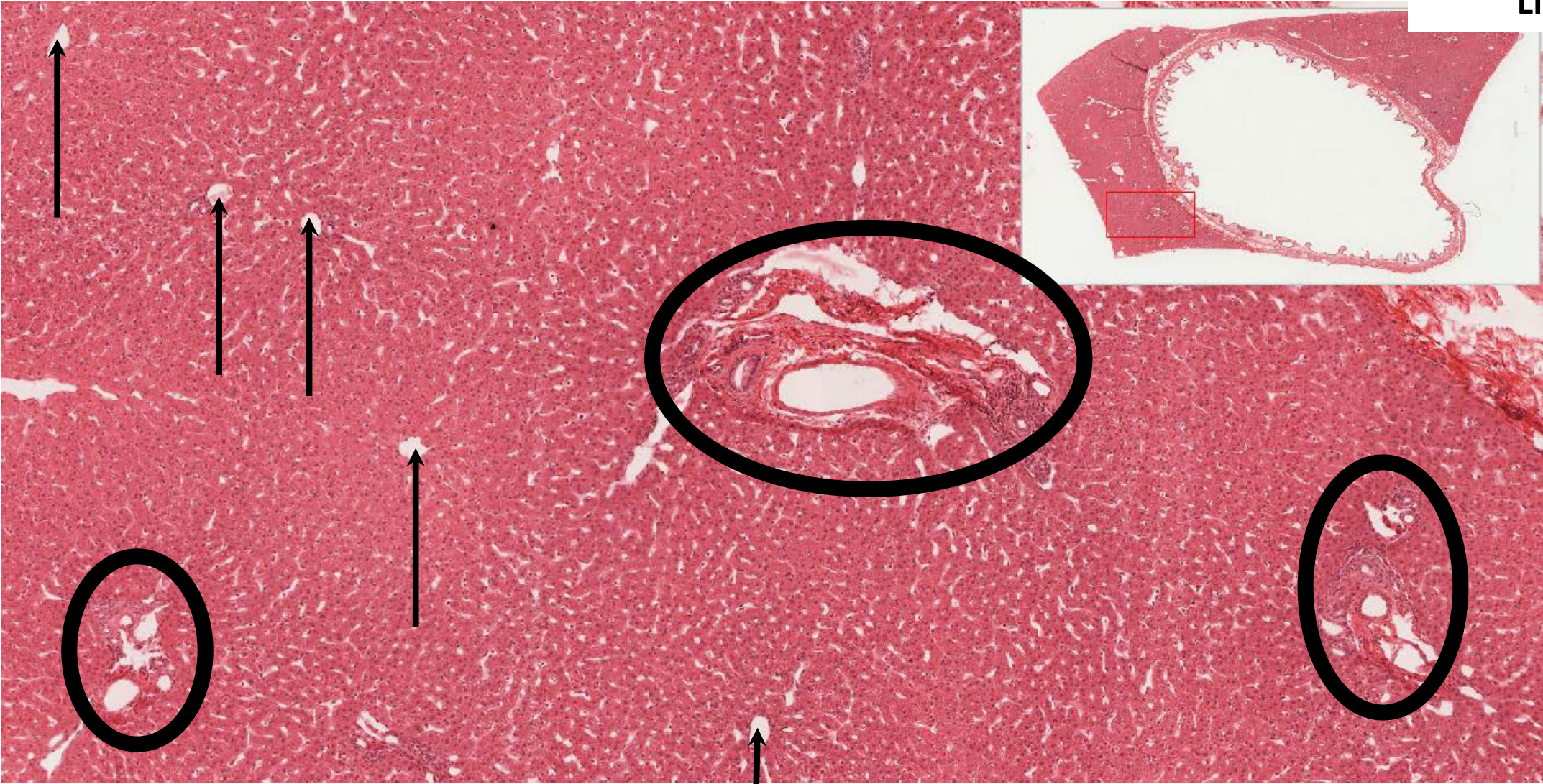
**Make sure Adobe Flash Player is enabled for this website.

**Pancreas Slide
(Higher magnification
in lobule)**



**Liver Slide
(Higher magnification
in lobule)**



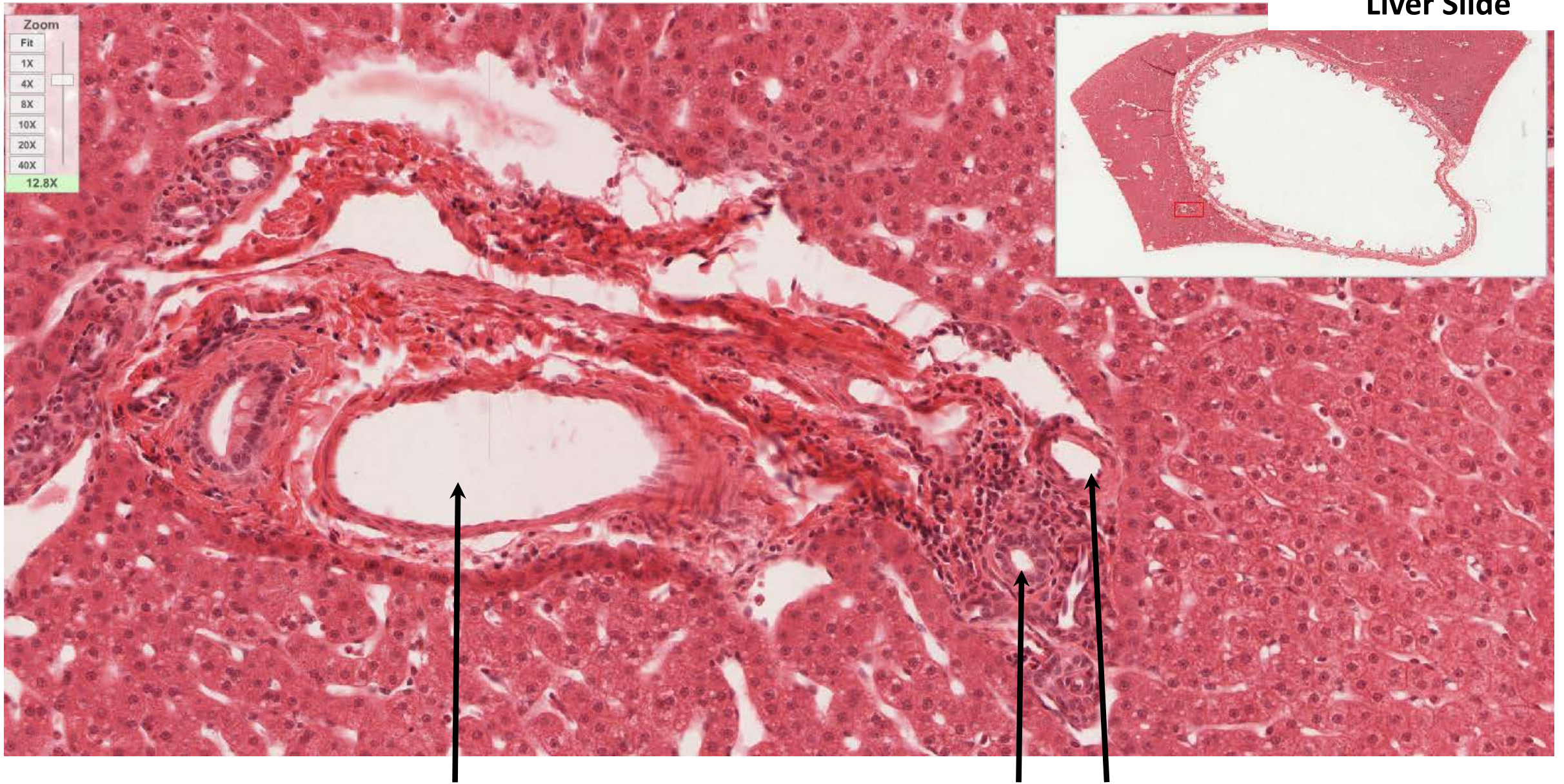


Arrows indicate central veins.

Interlobular Areas

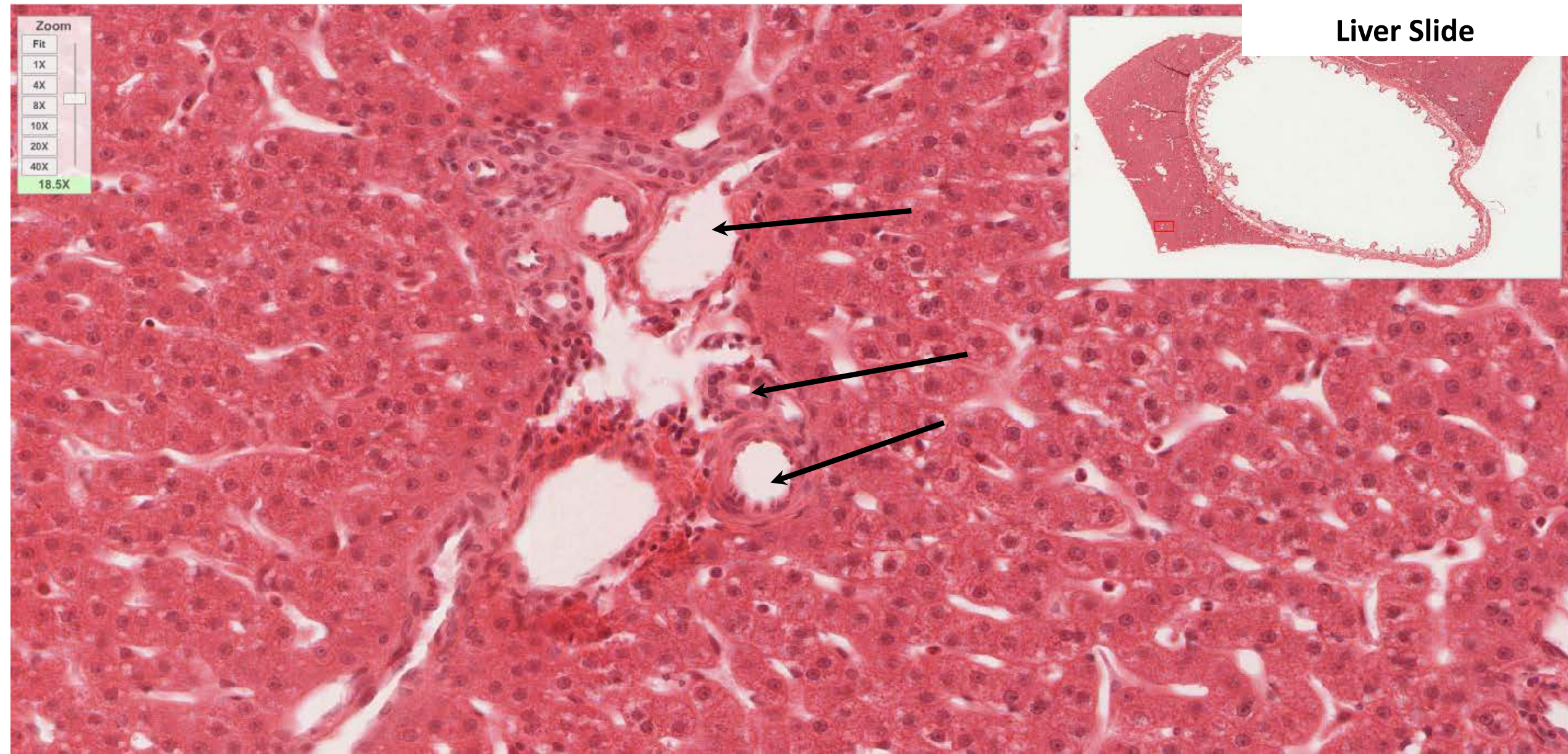
Interlobular Areas have a lot of tubes collected together here.

Liver Slide



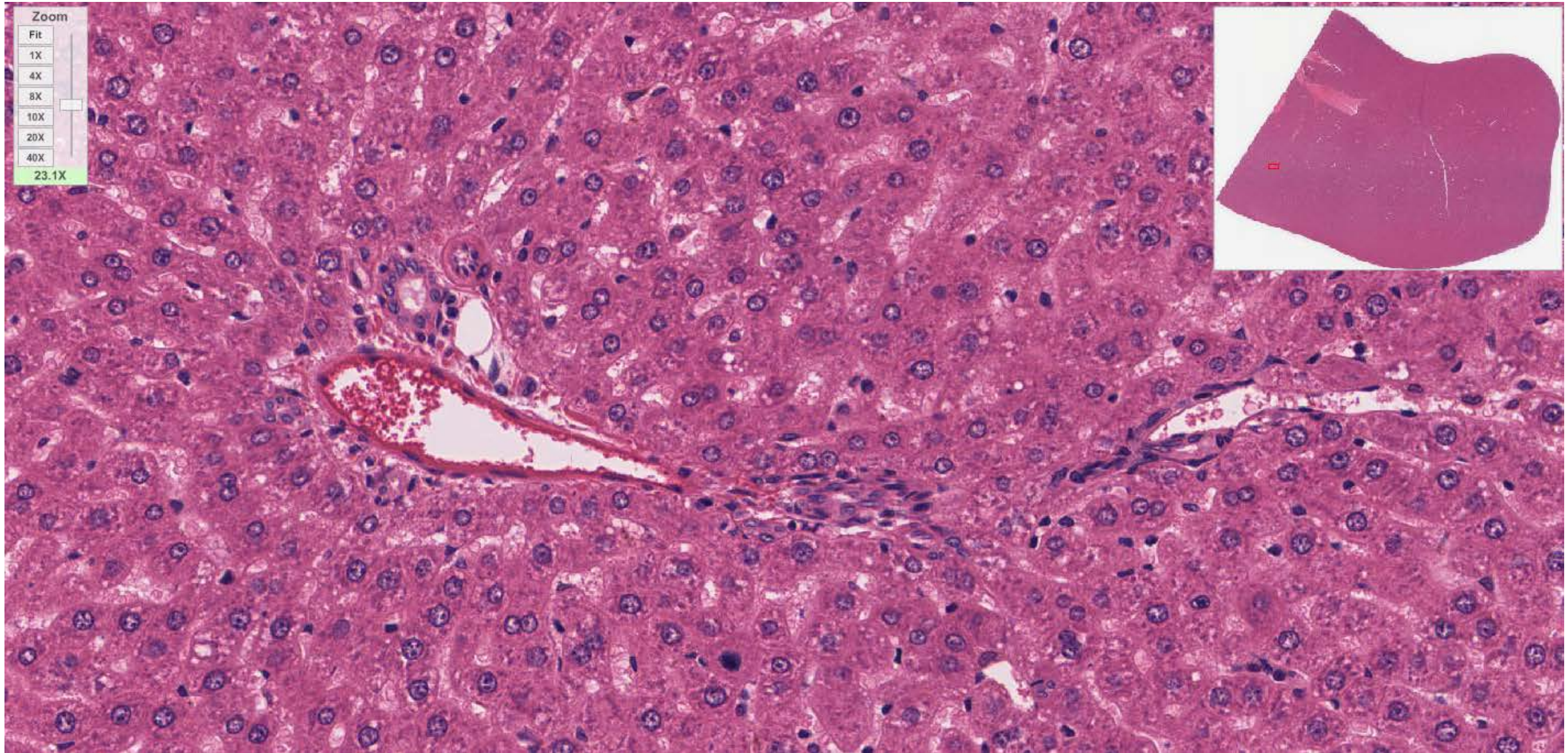
Arrows indicate 3 different types of tubes. Can you find more of them?

Liver Slide

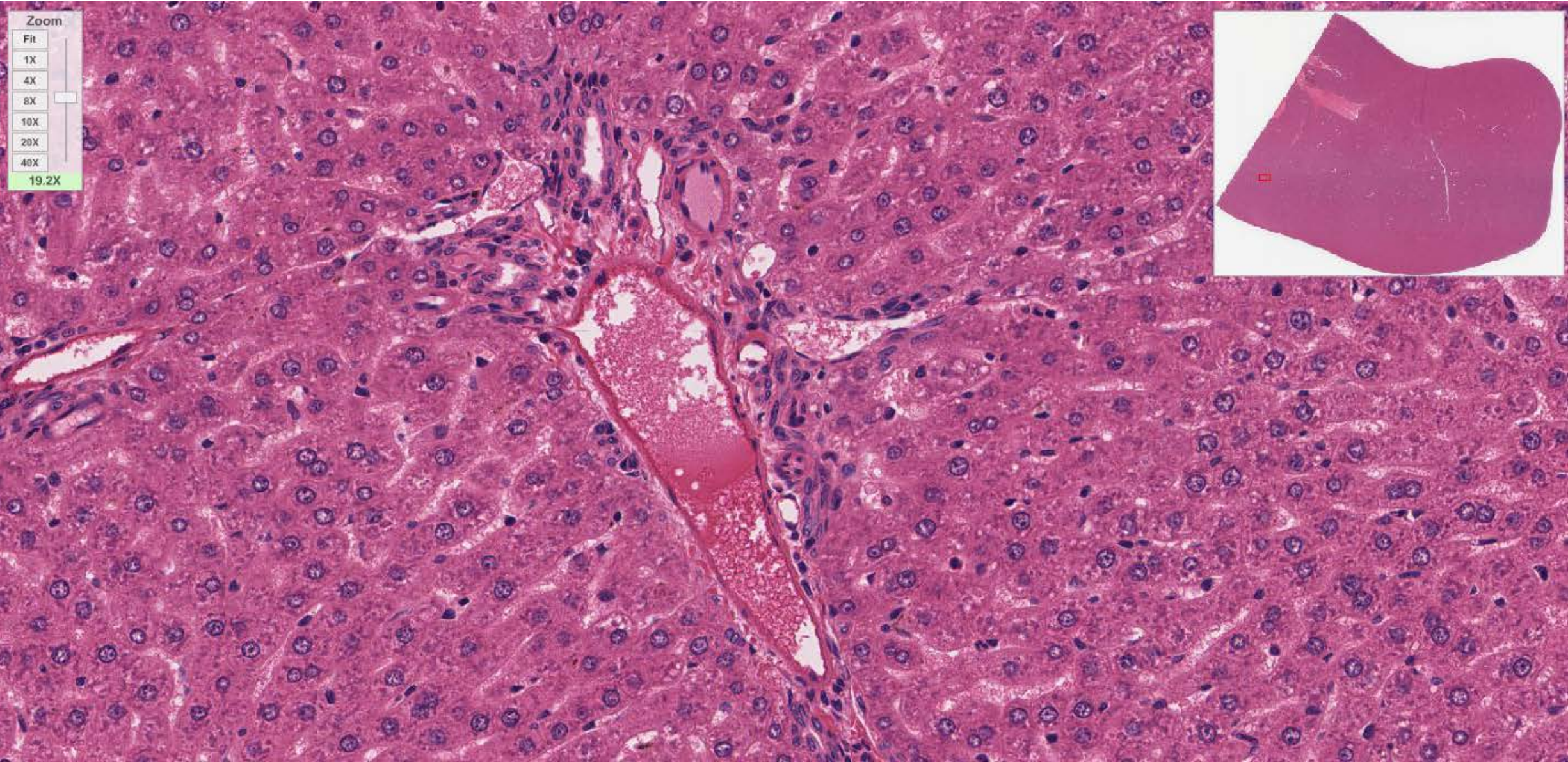


Arrows indicate 3 different types of tubes. Can you find more of them?

Liver Slide



Liver Slide



Liver Slide

